

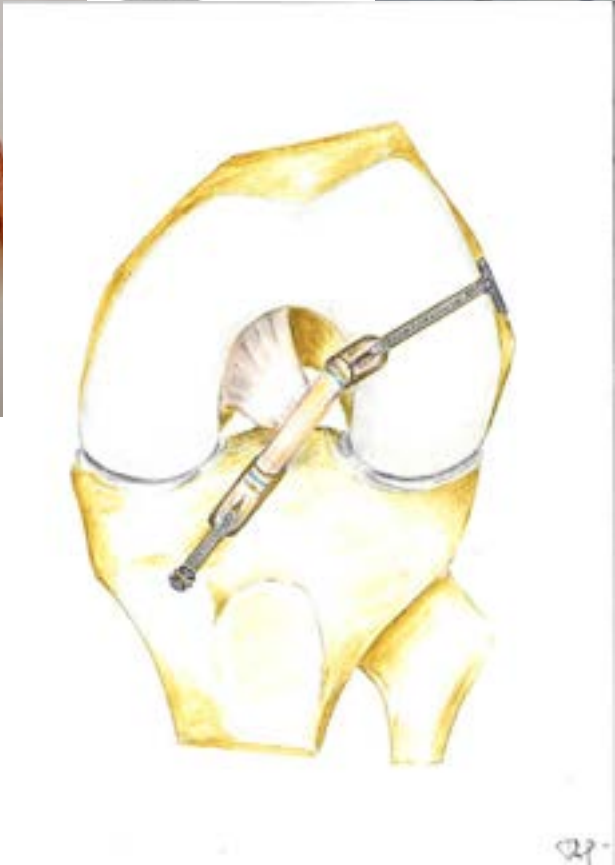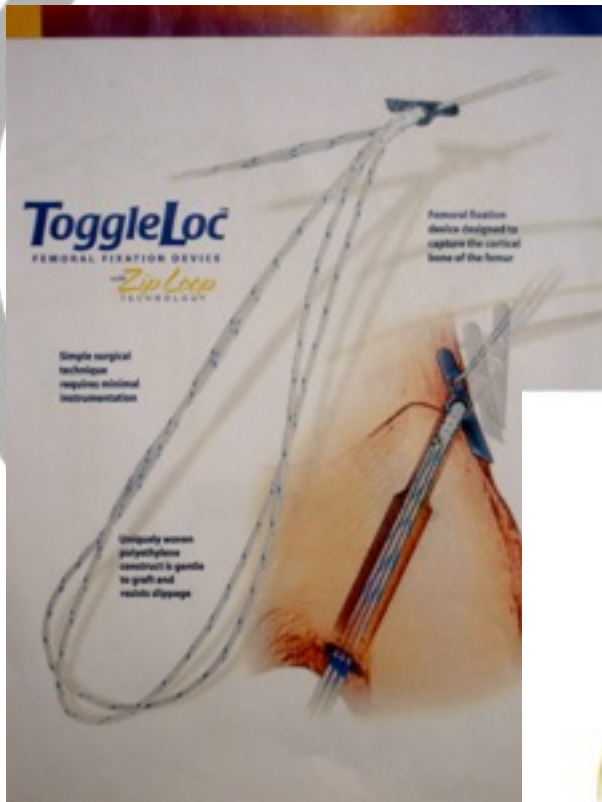DTZ4
Ligamentoplasty of ACL
Semi-tendinosus for 4 branch transplant
All Inside

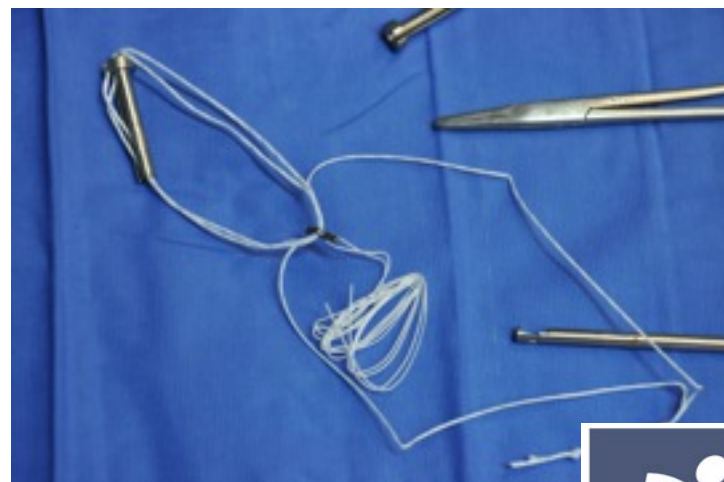
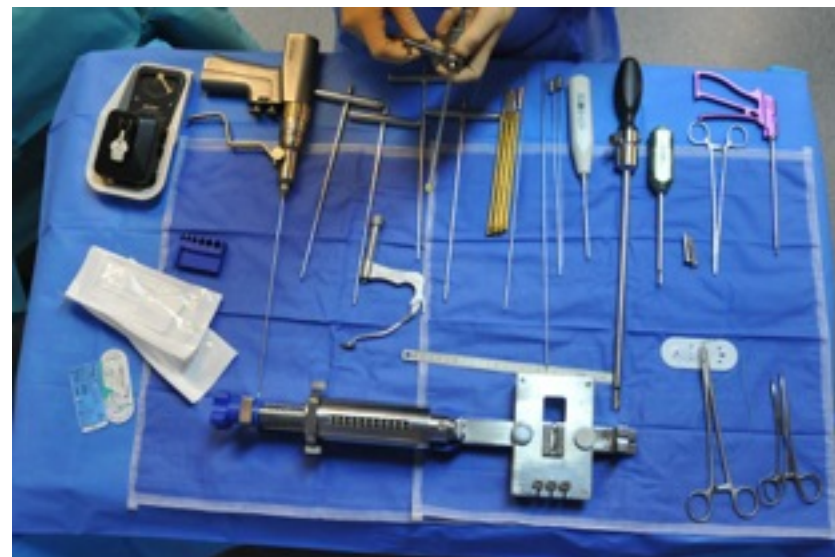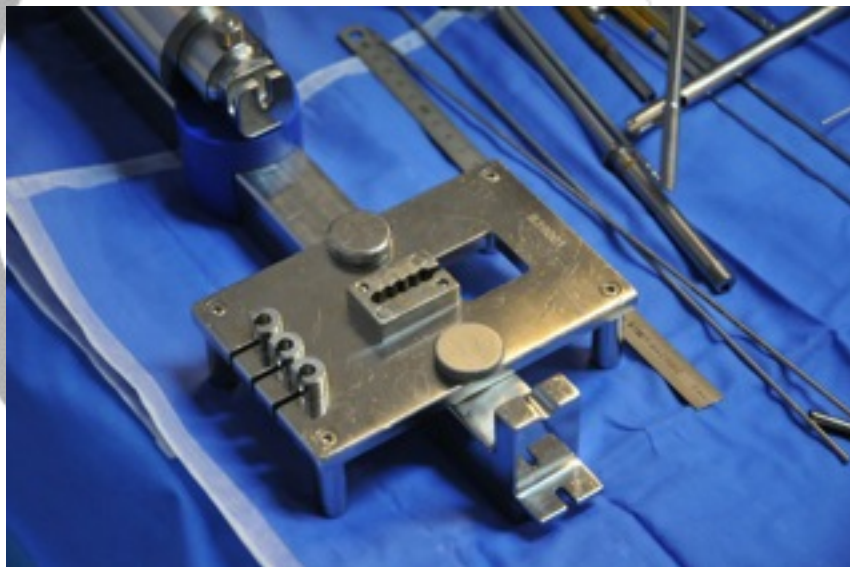
Dr Jean-Christophe DURAND

Clinique St Charles
LYON (France)

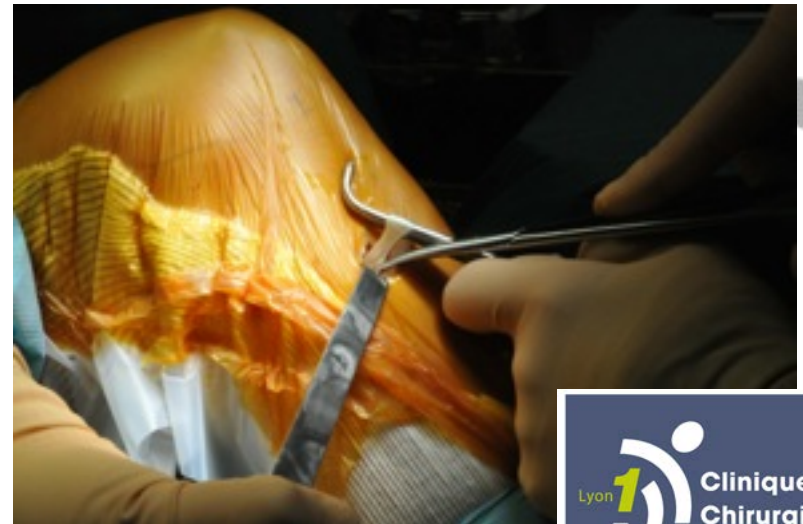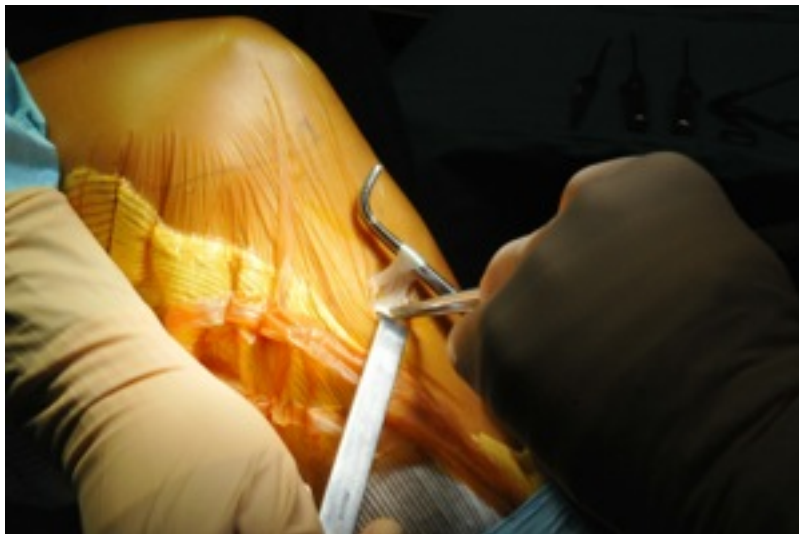
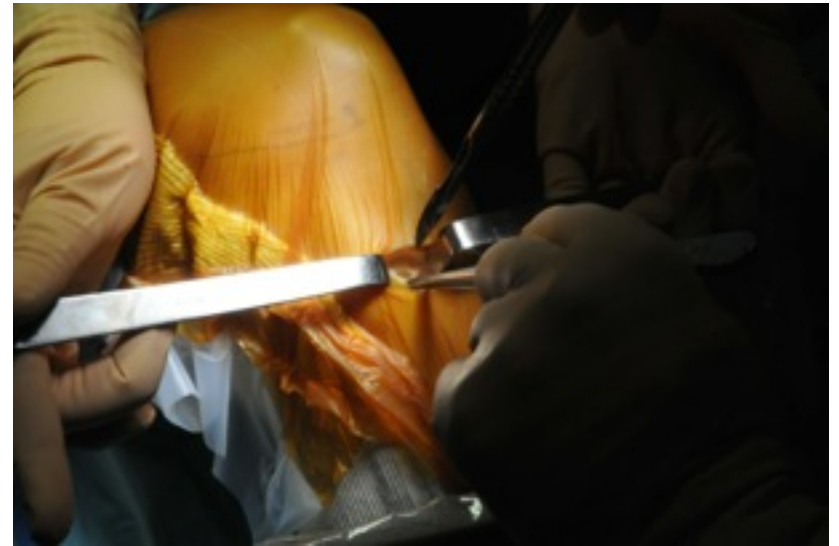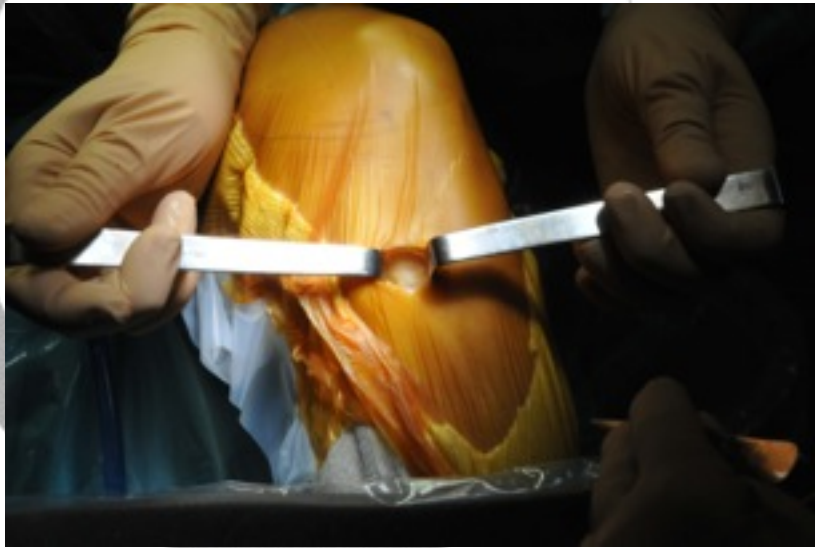




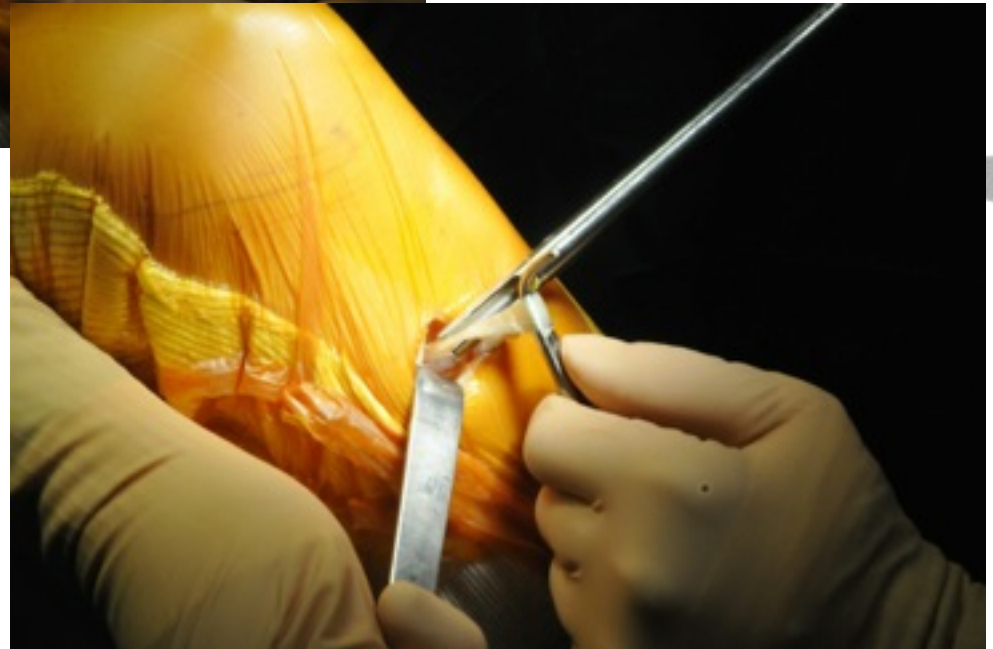
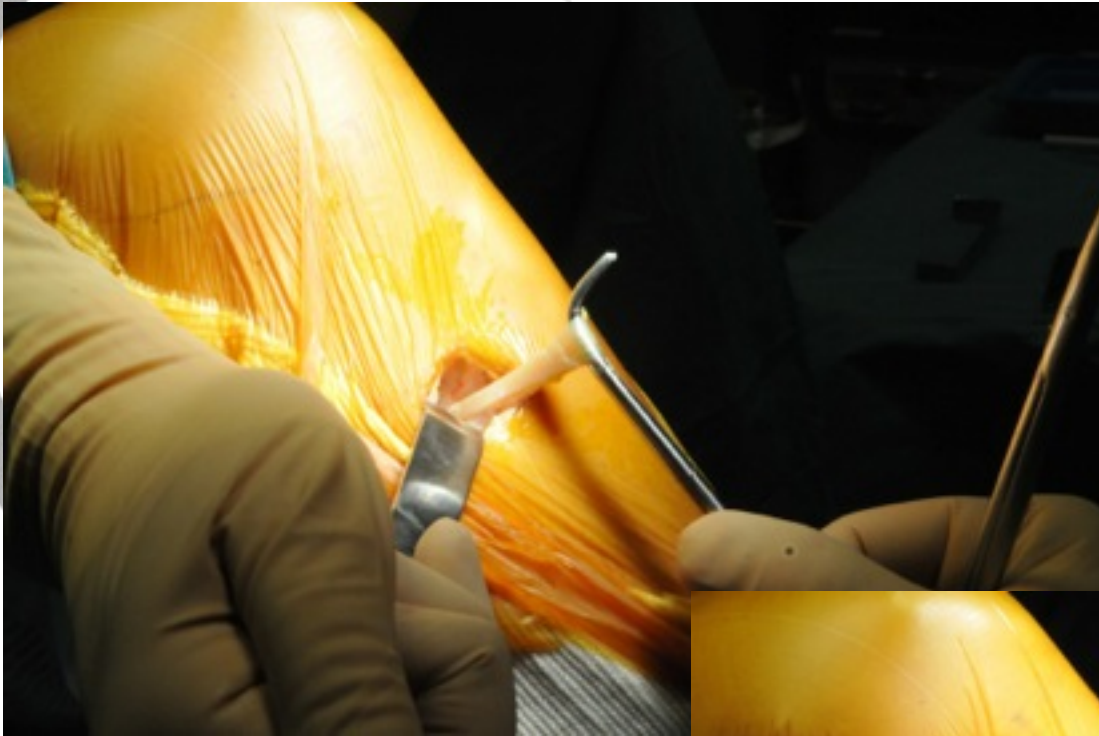
BOX OF INSTRUMENT

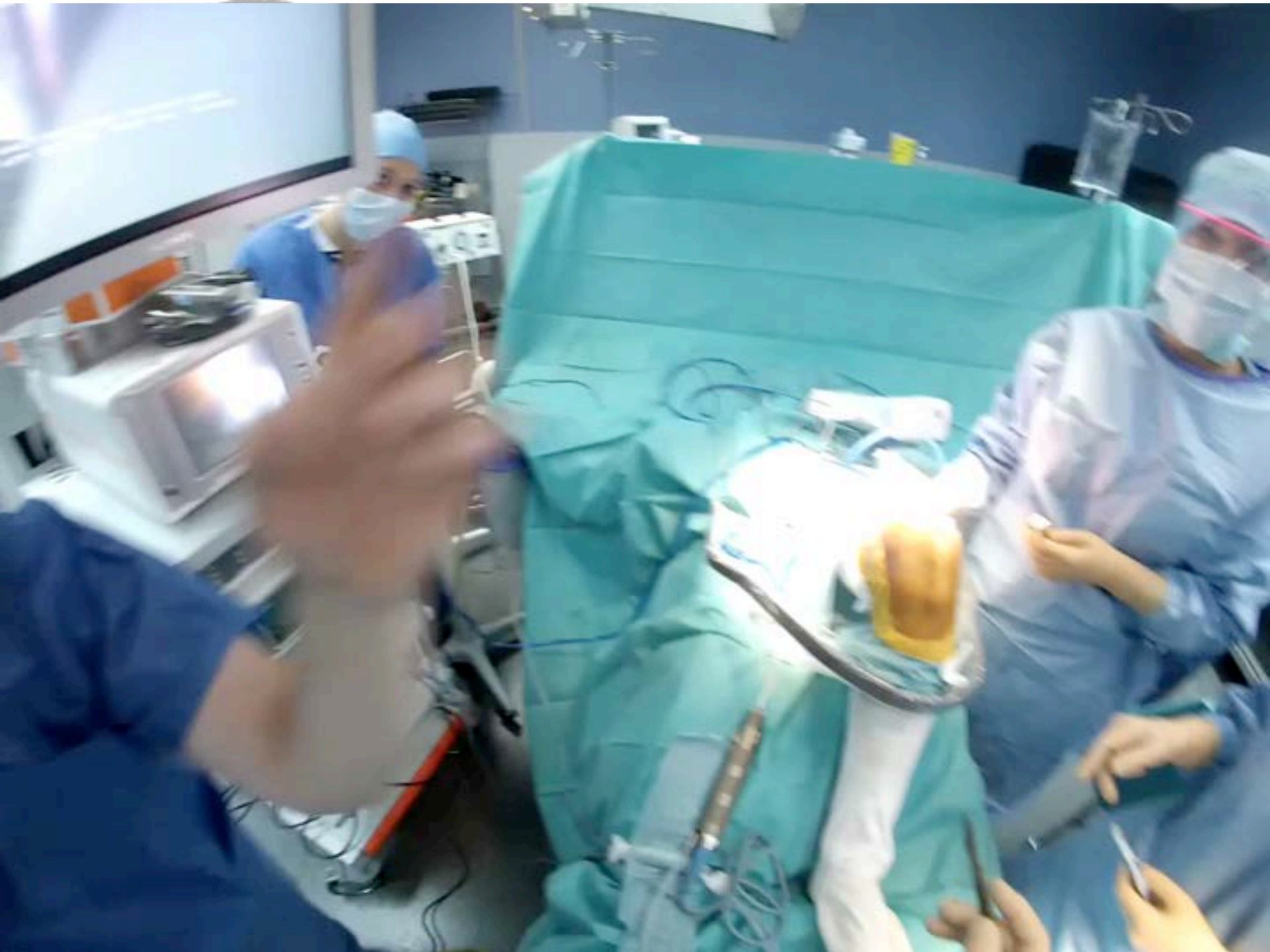

DISSECTION OF THE TRANSPLANT

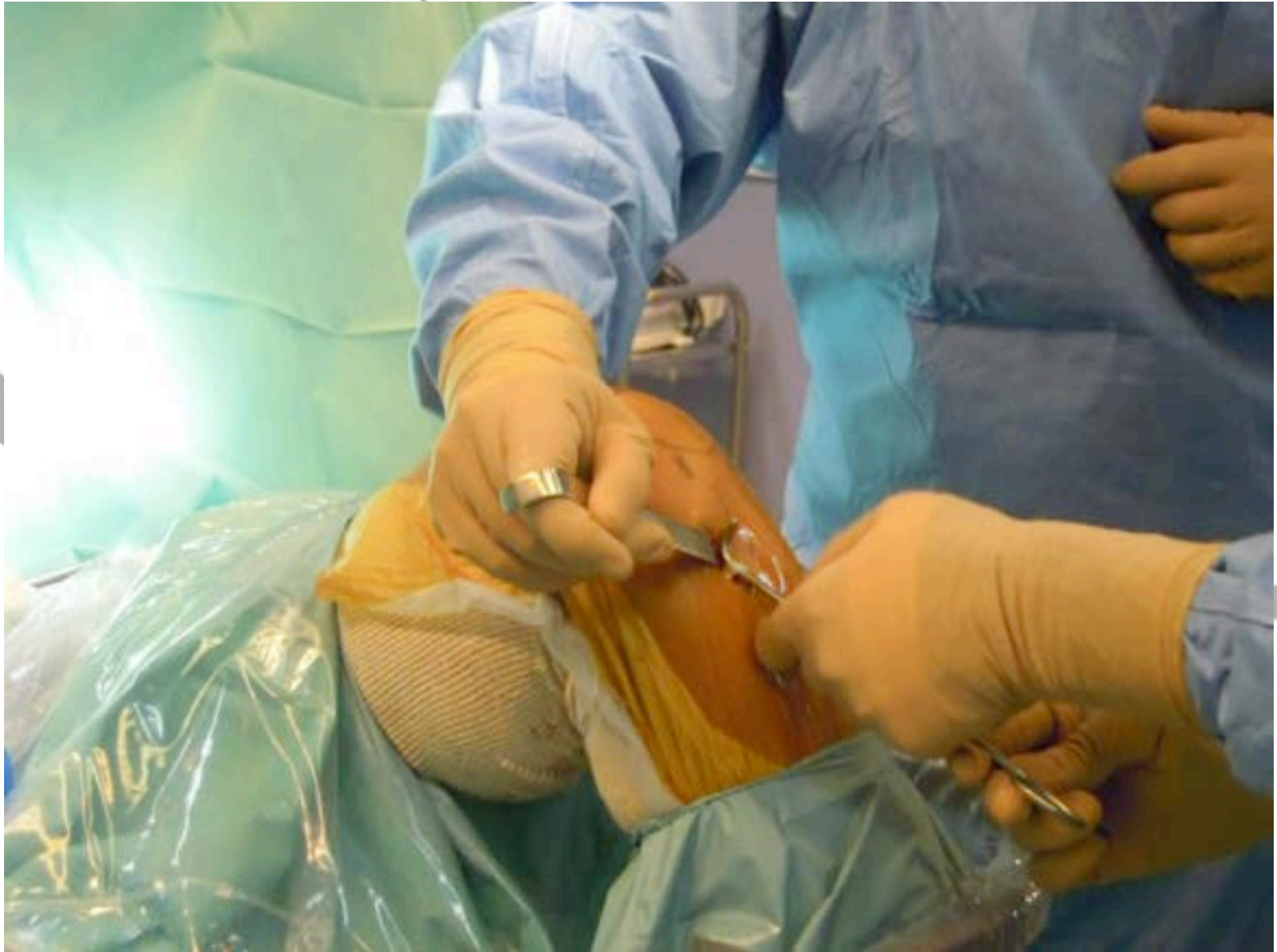

DISSECTION OF THE TRANSPLANT

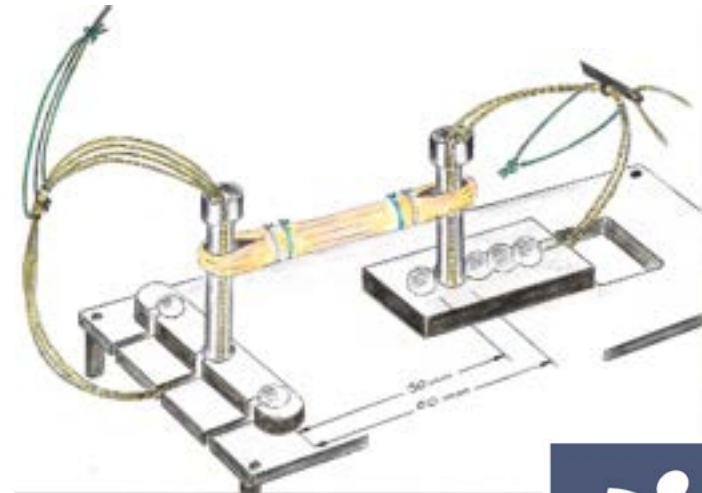






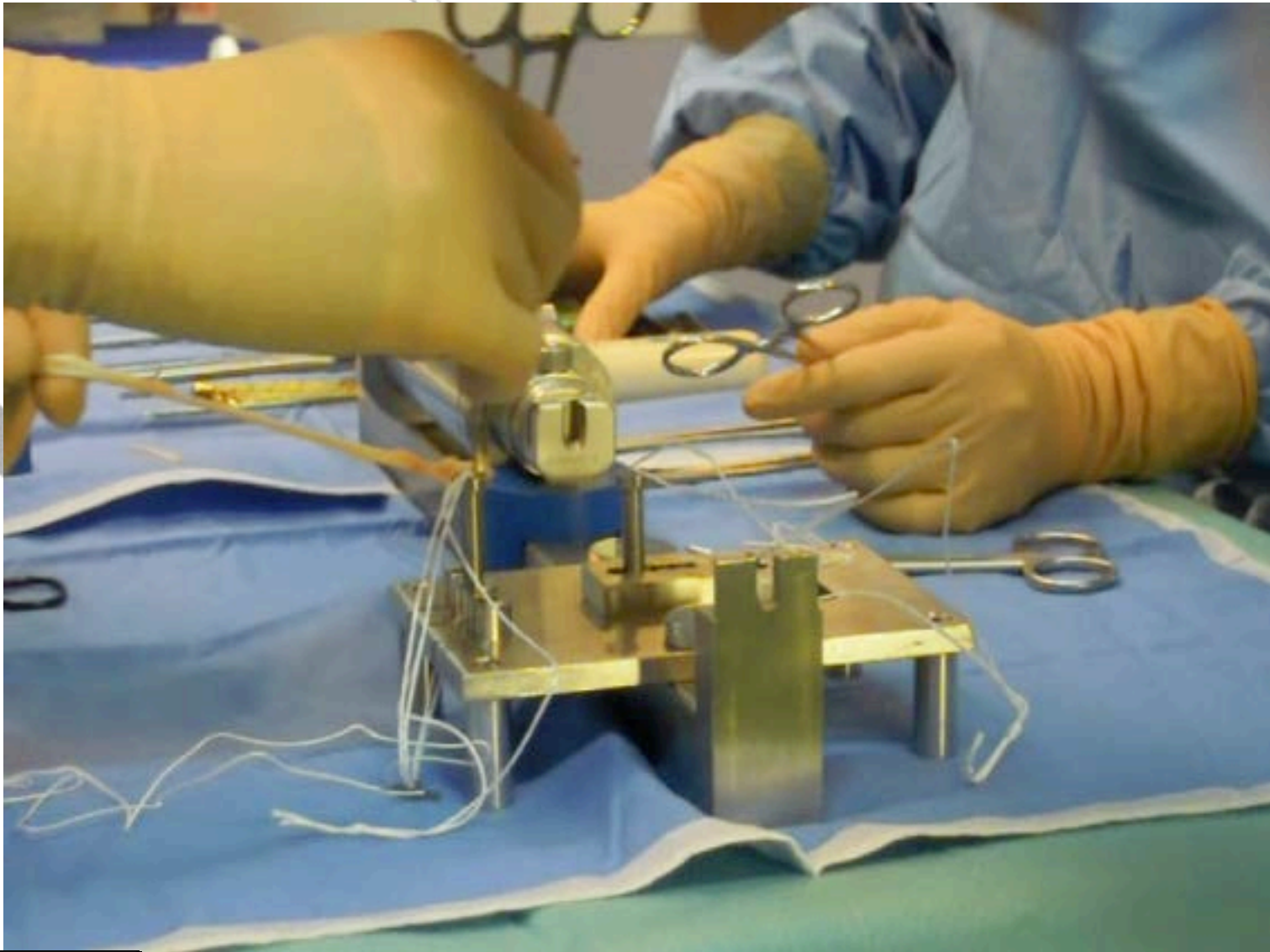
DISSECTION OF THE TRANSPLANT



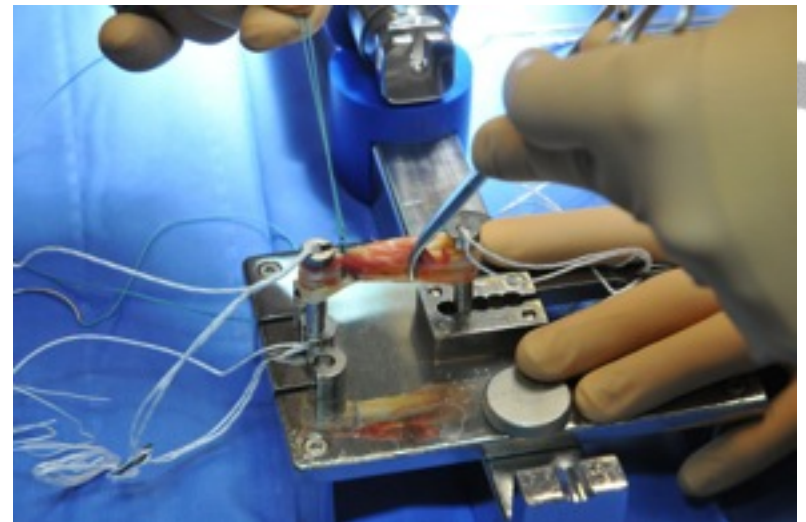

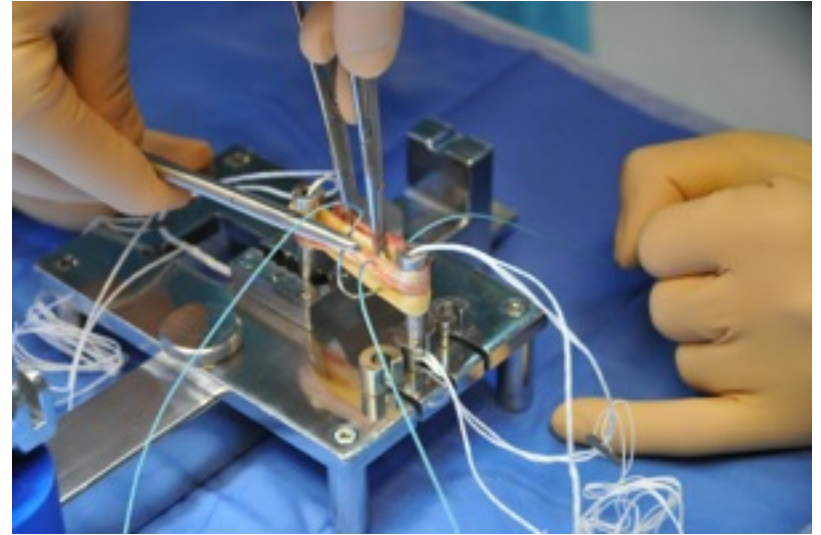
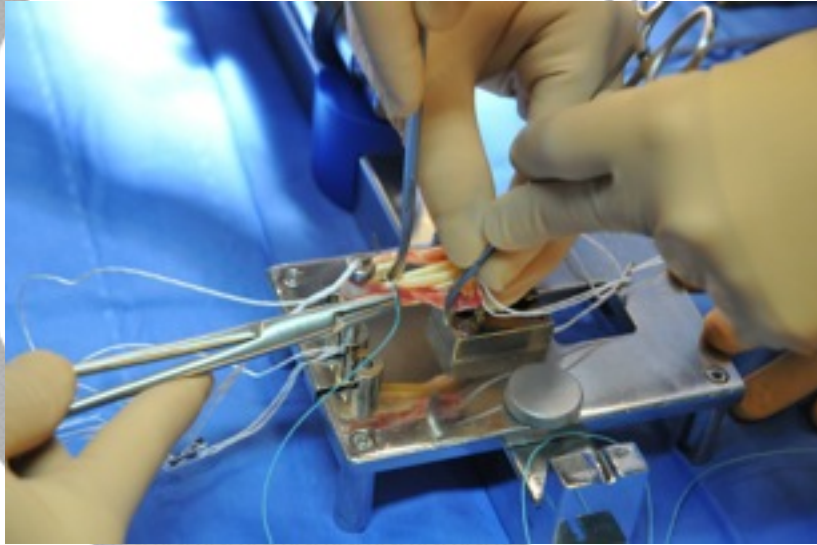
PREPARATION OF THE GRAFT



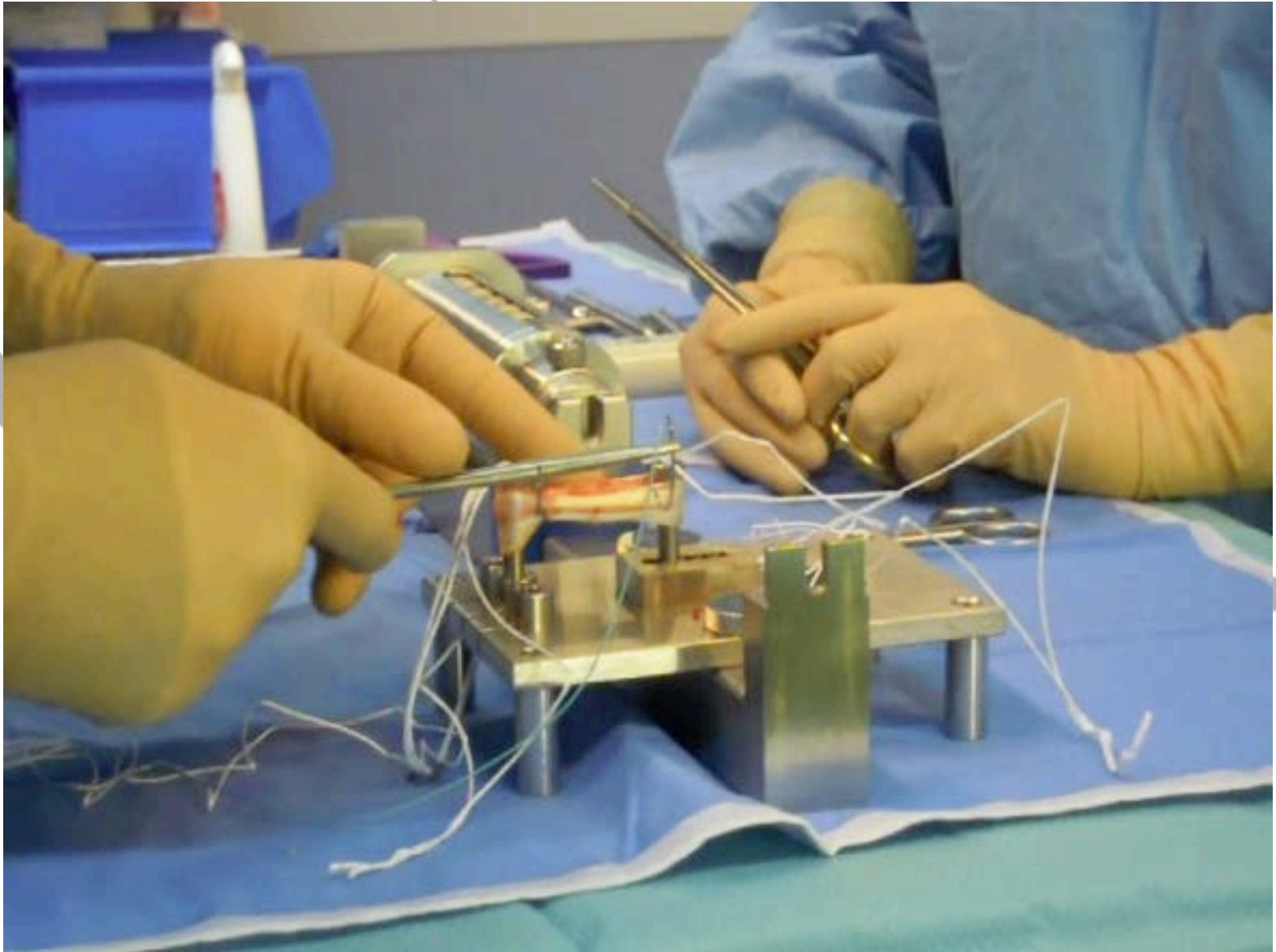
PREPARATION OF THE GRAFT

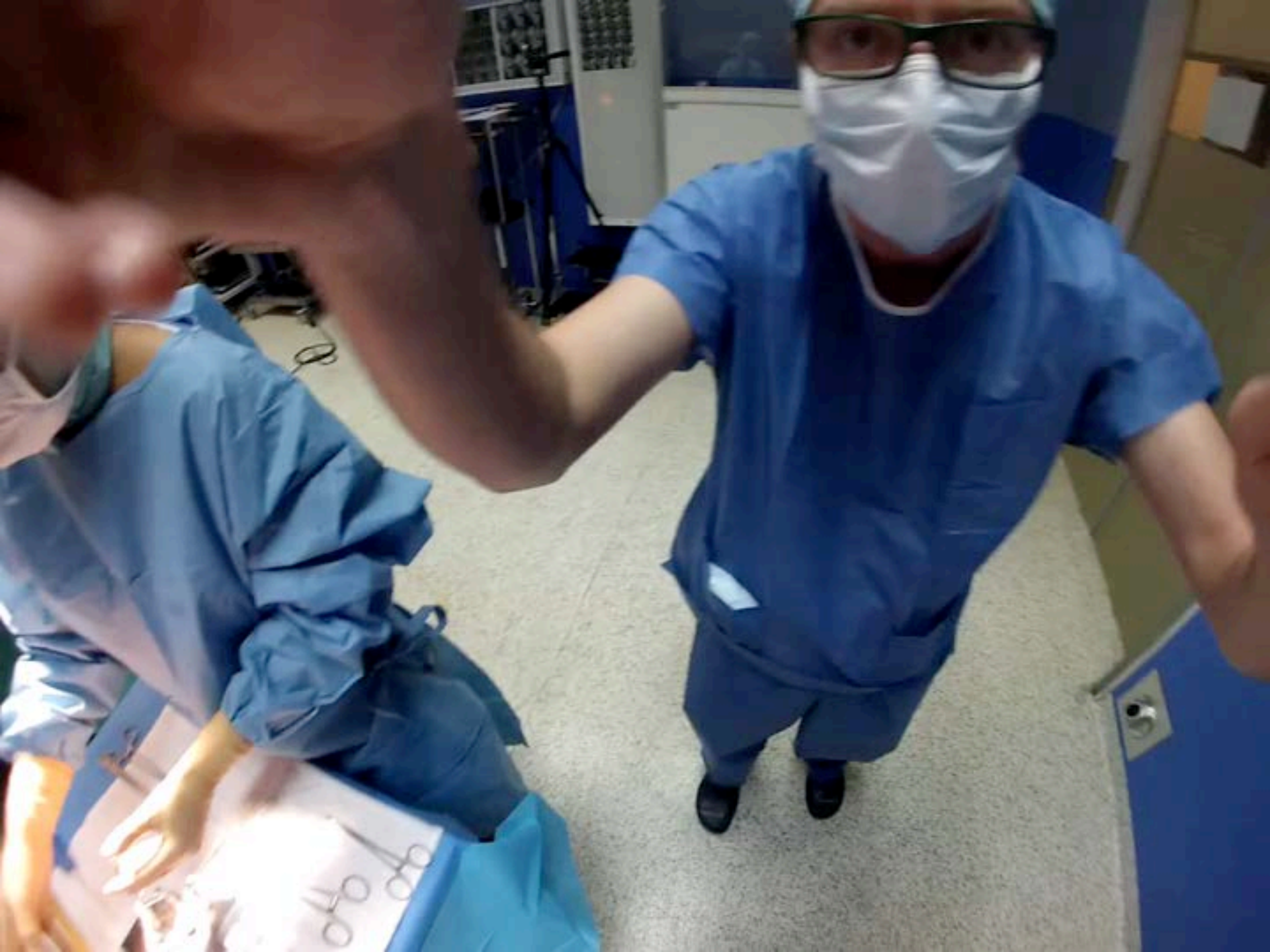

SUTURE OF THE GRAFT

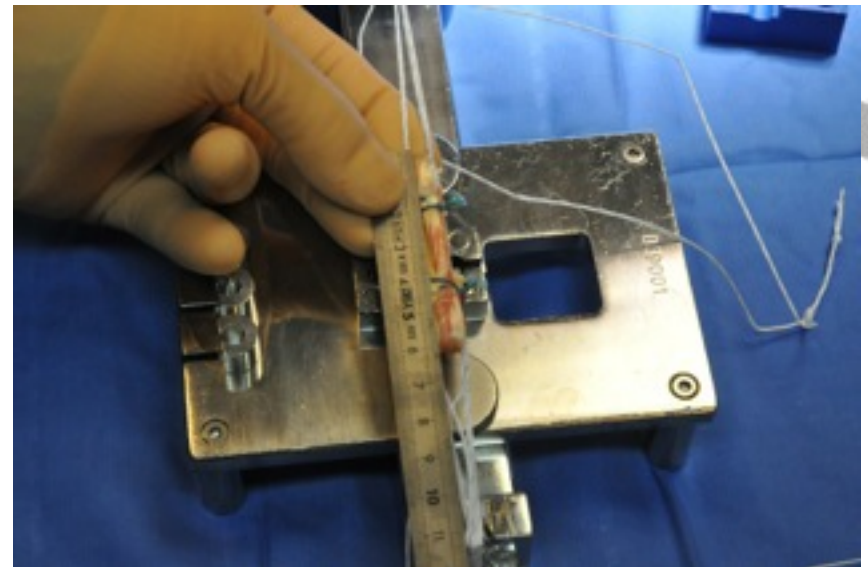
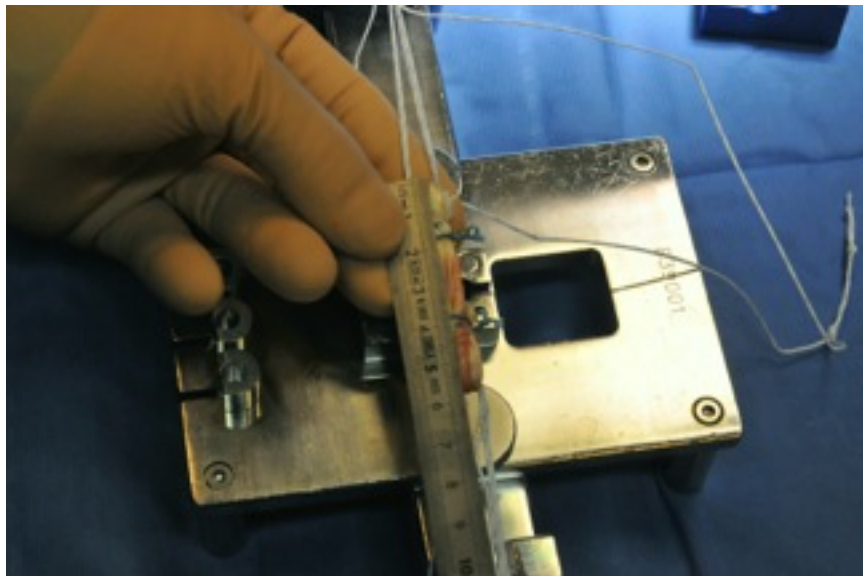



SUTURE OF THE GRAFT

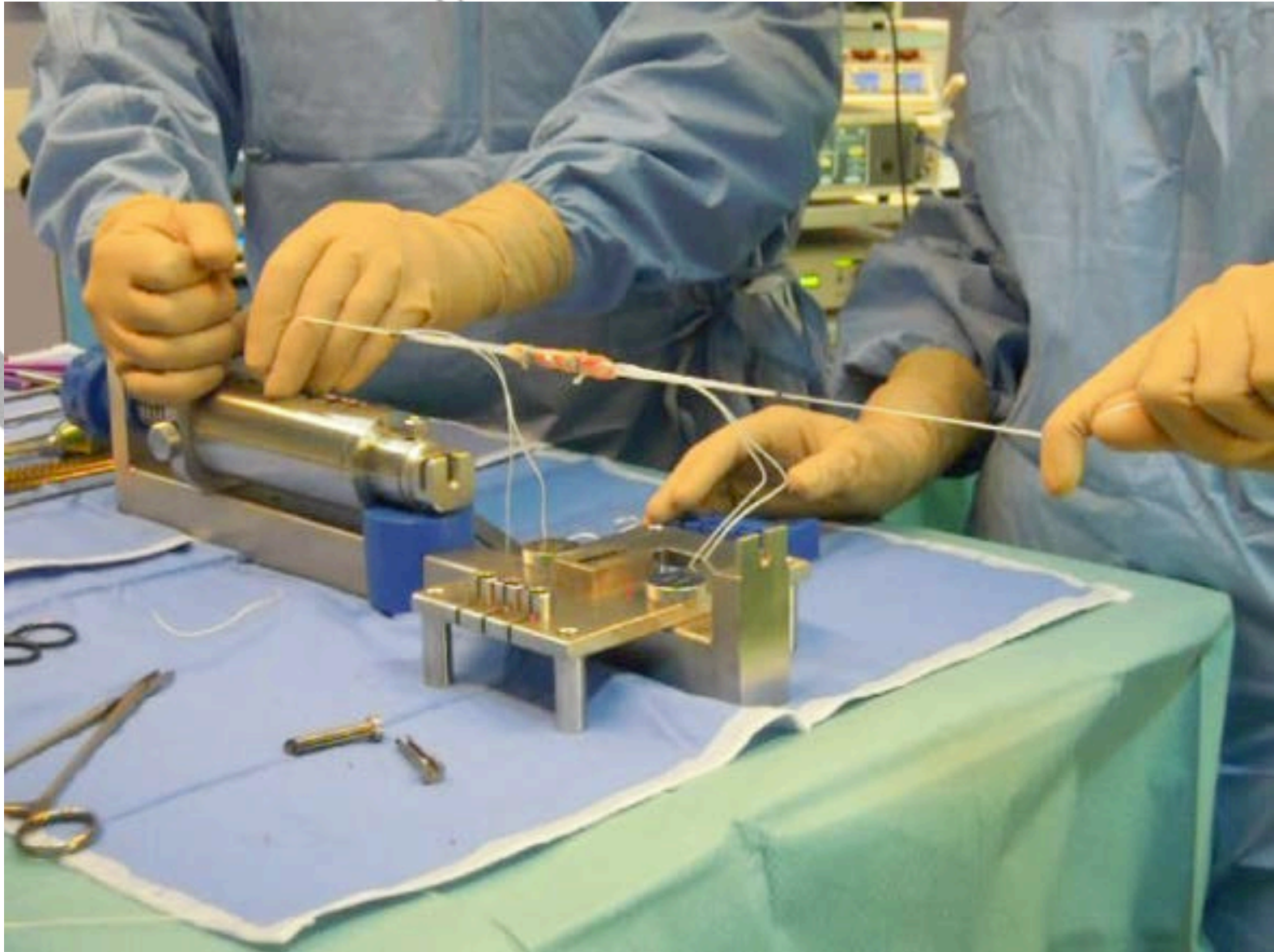




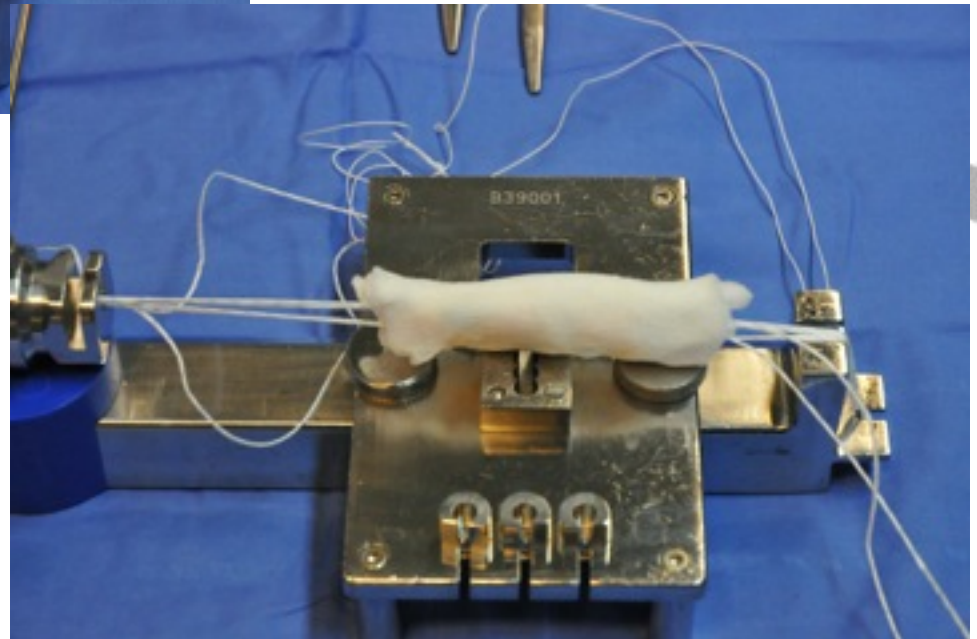
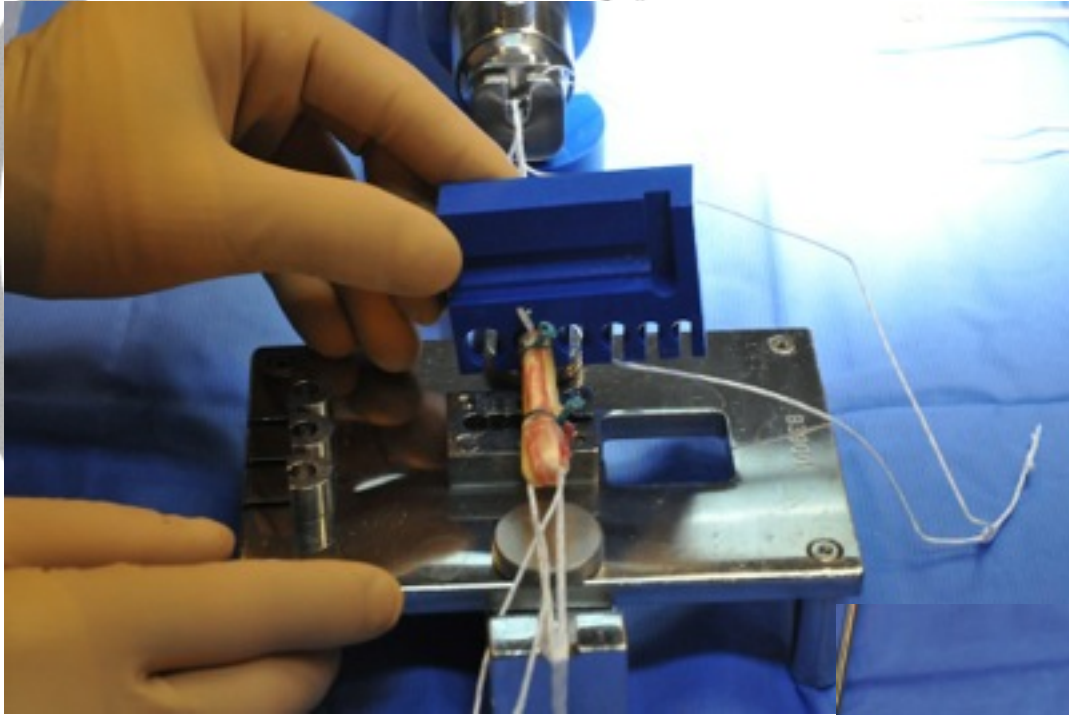
TENSIONING DEVICE AND CALIBRATION



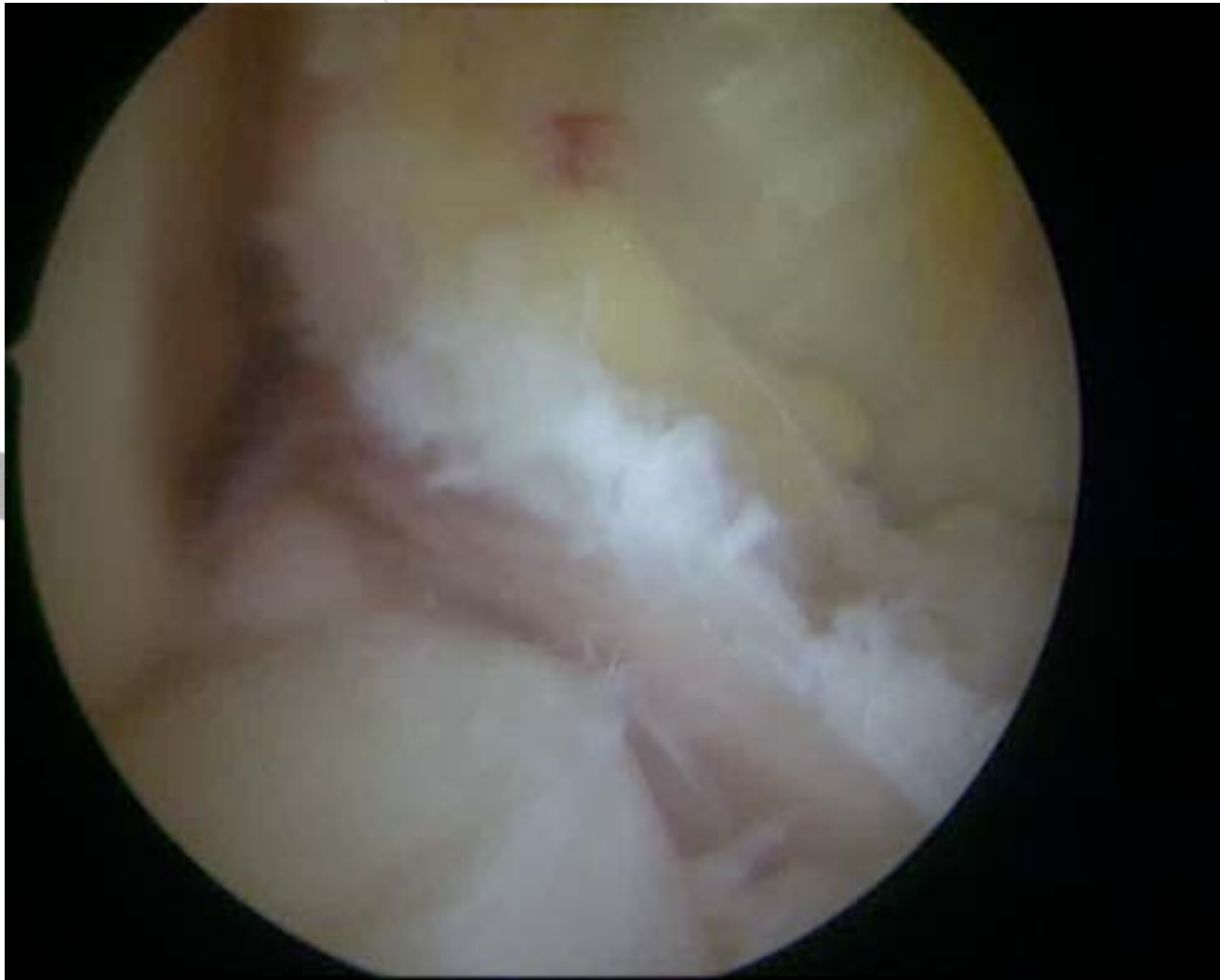TENSIONING DEVICE AND CALIBRATION



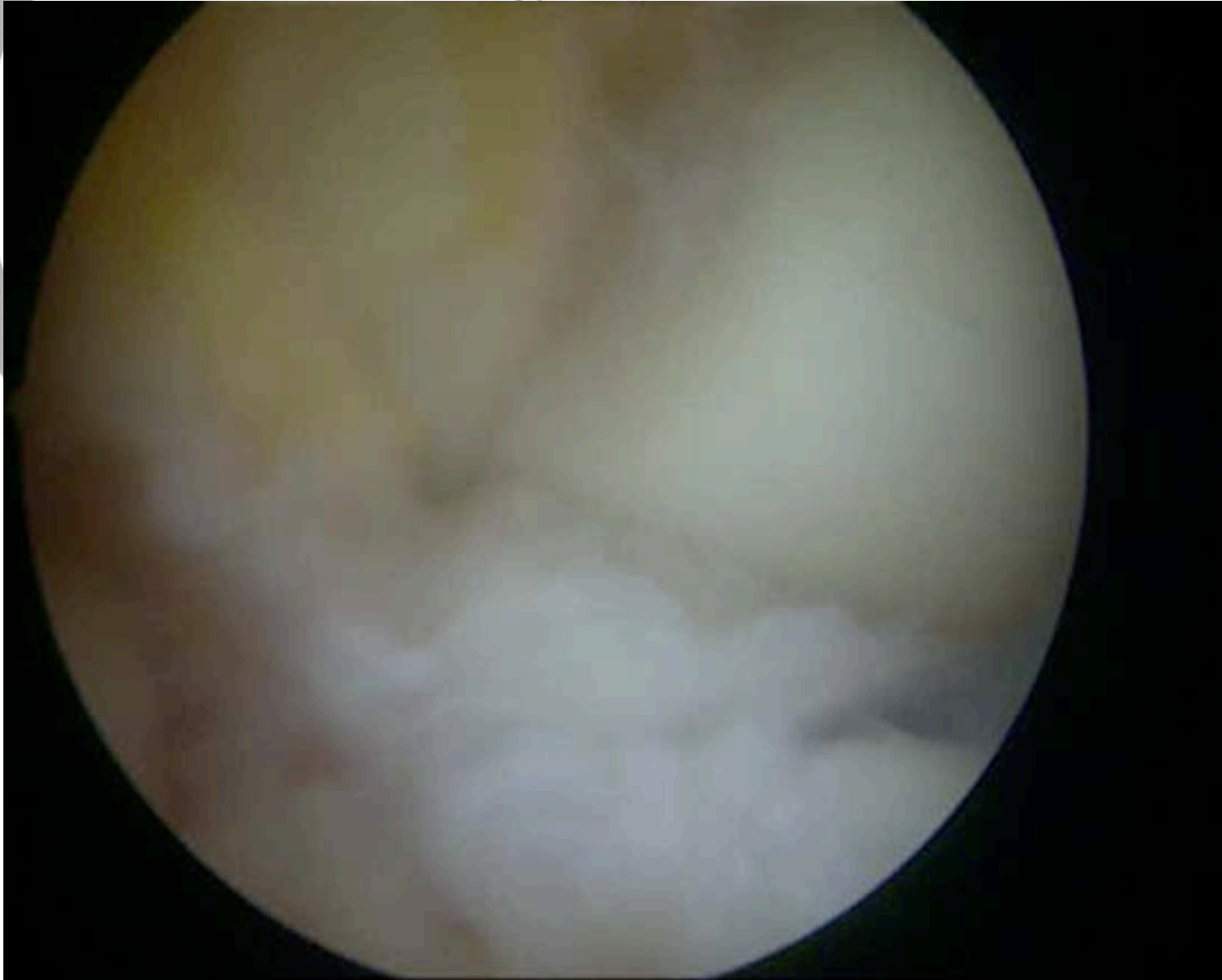
TENSIONING DEVICE AND CALIBRATION



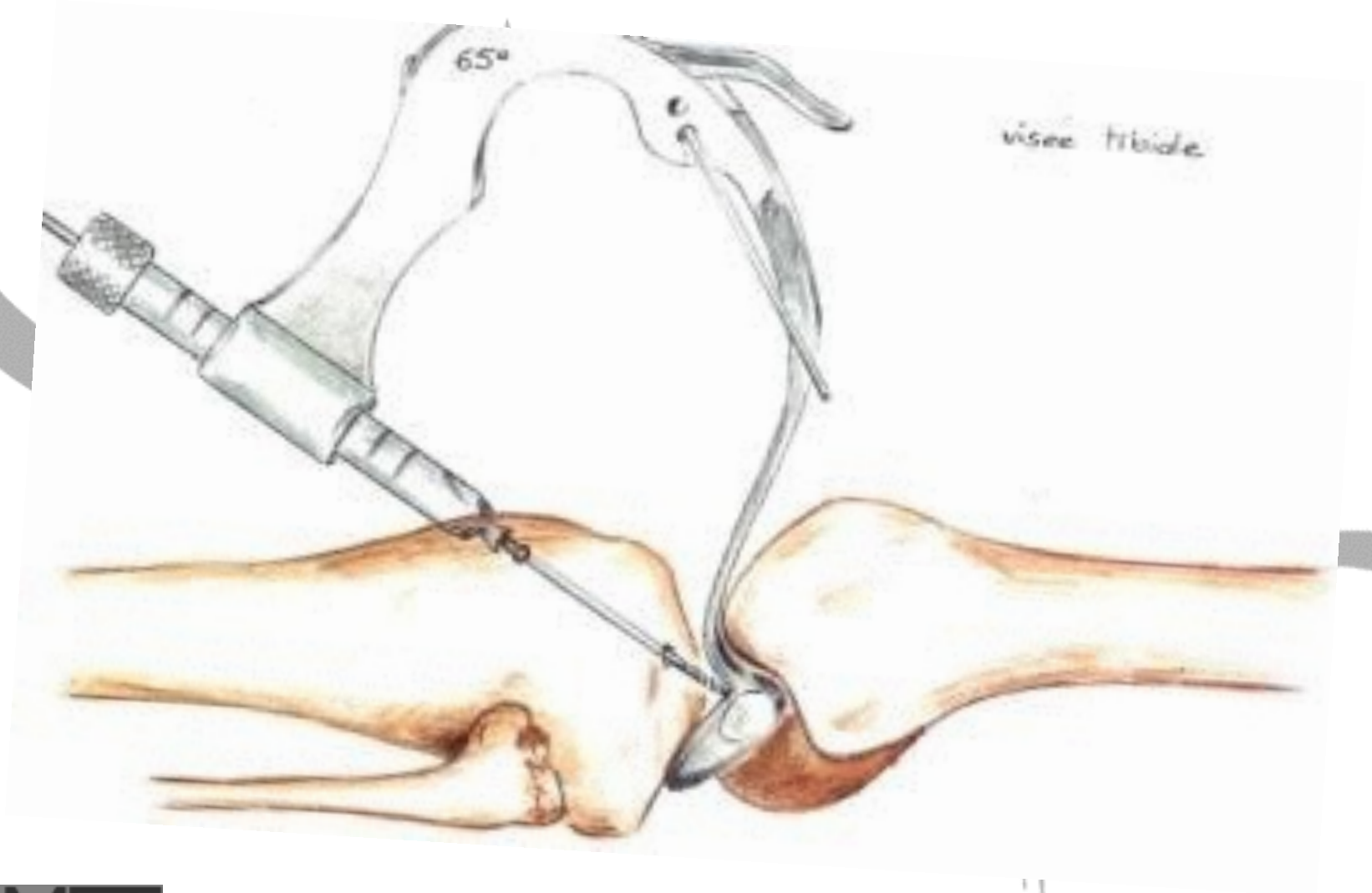
ARTHROSCOPIC LESIONAL CHECK-UP

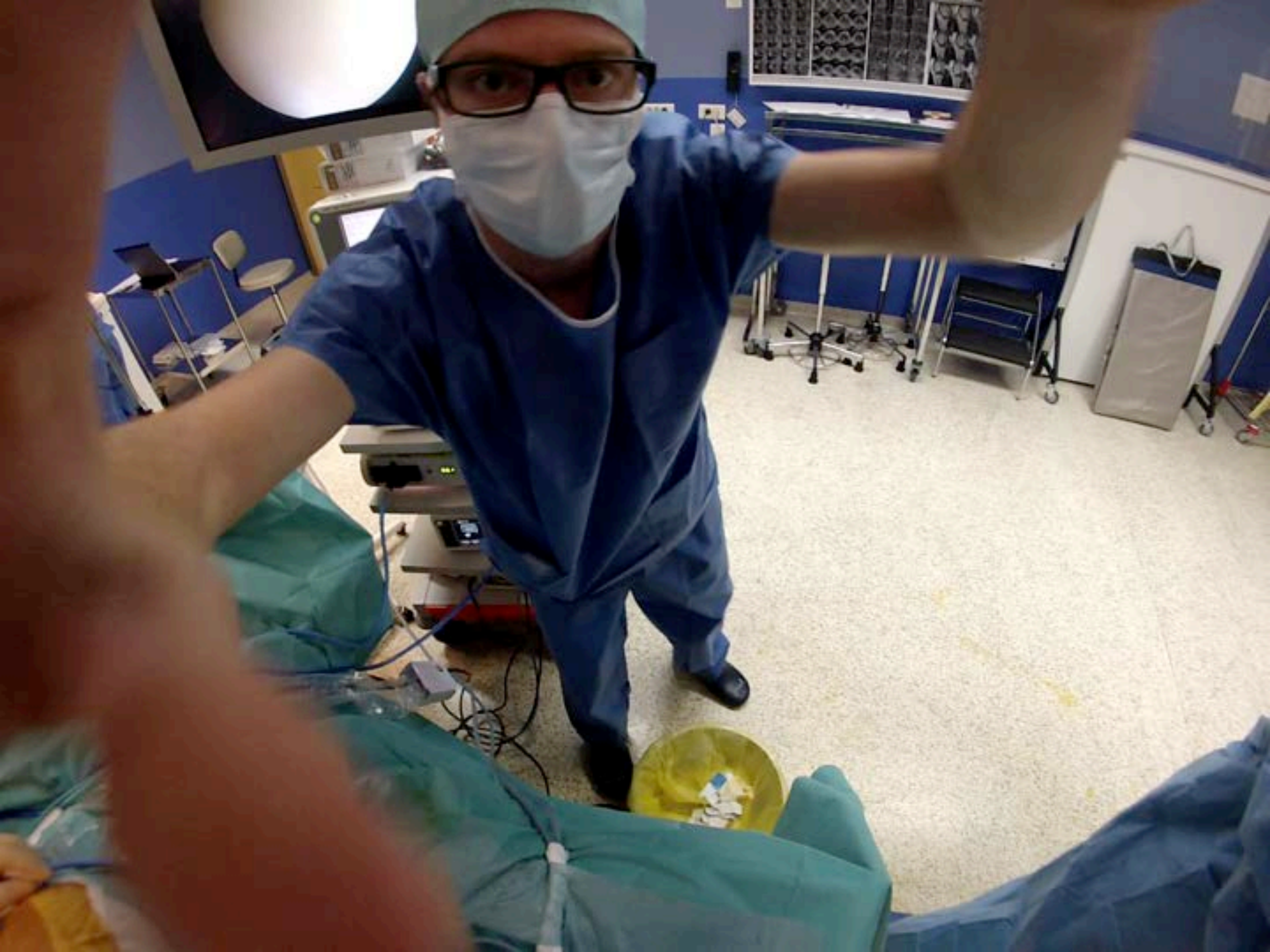

ARTICULAR CLEANING

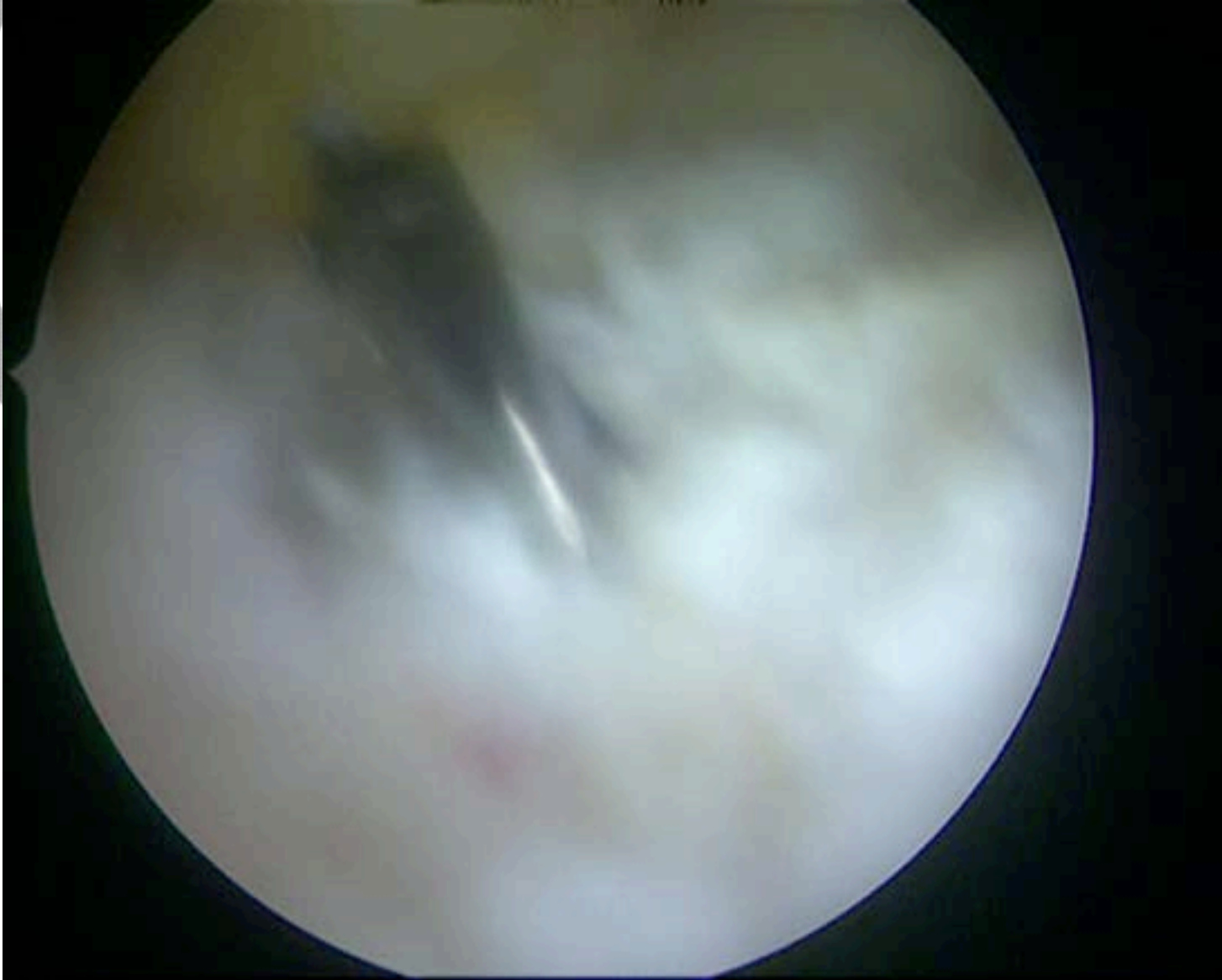


AIMED TIBIAL IN EXTENSION

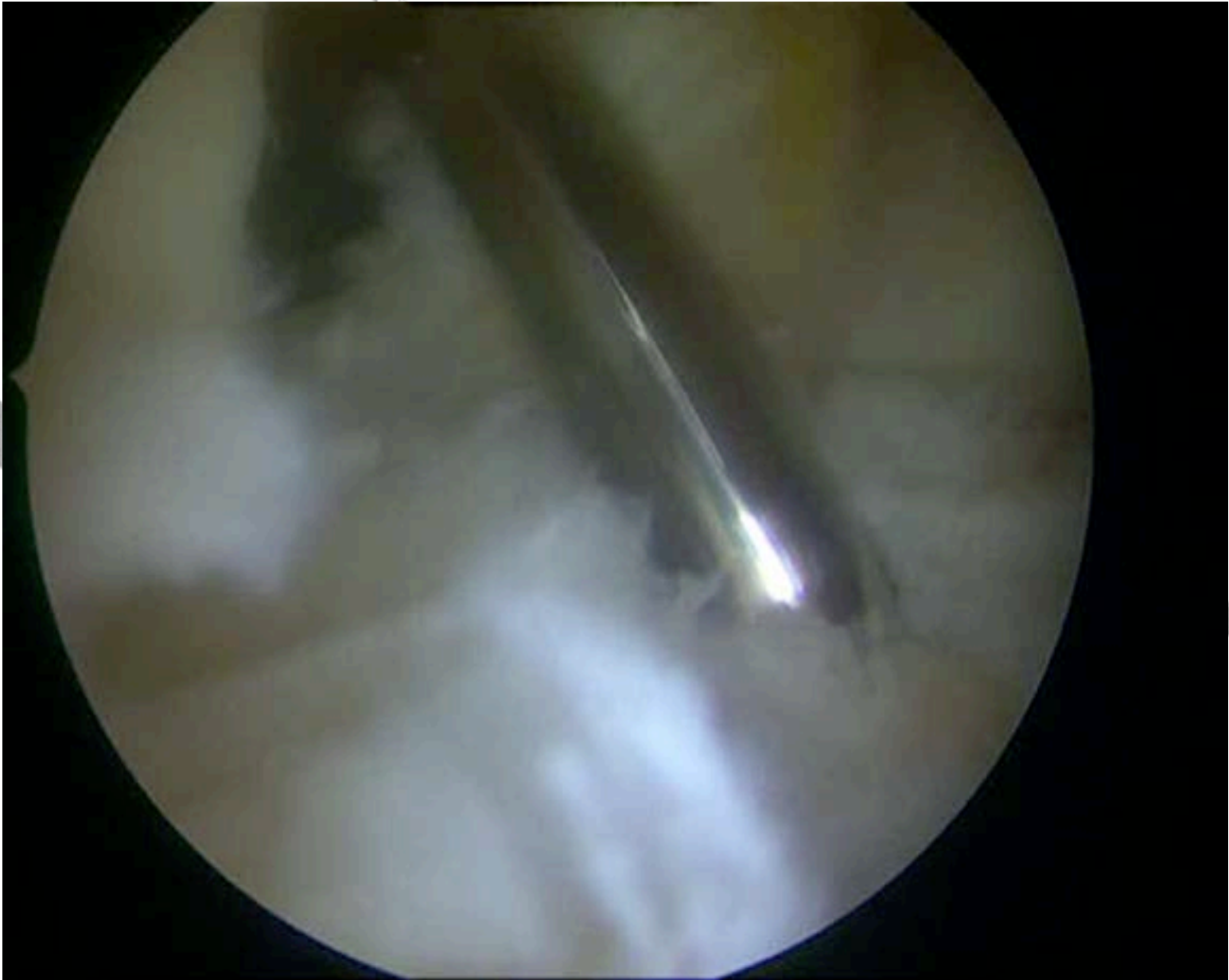



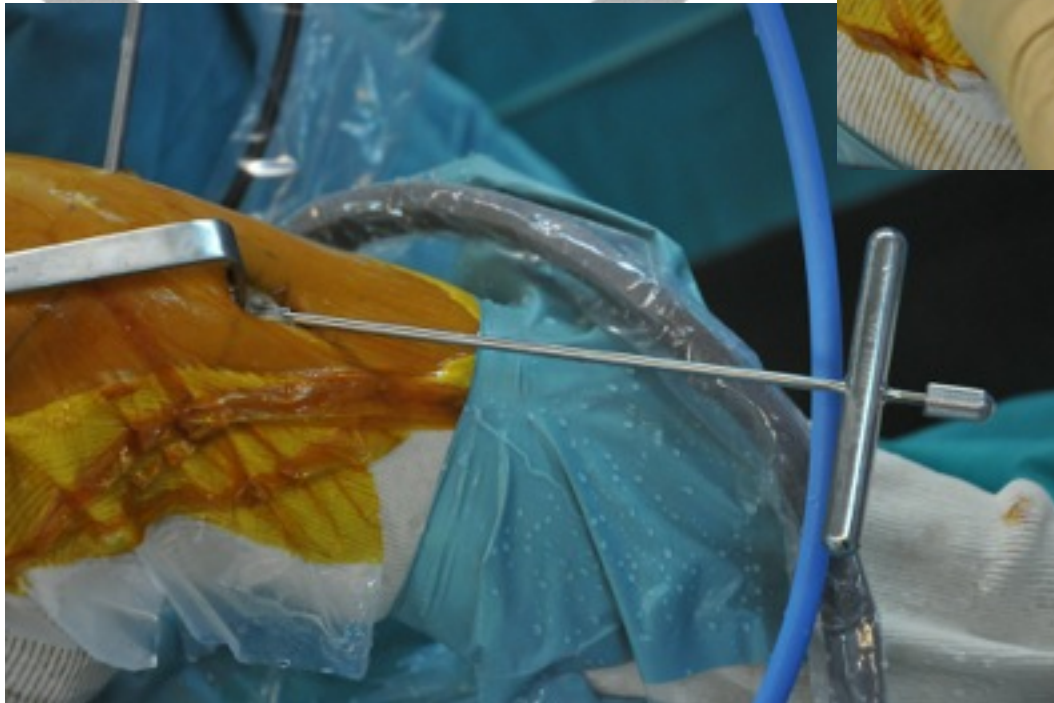
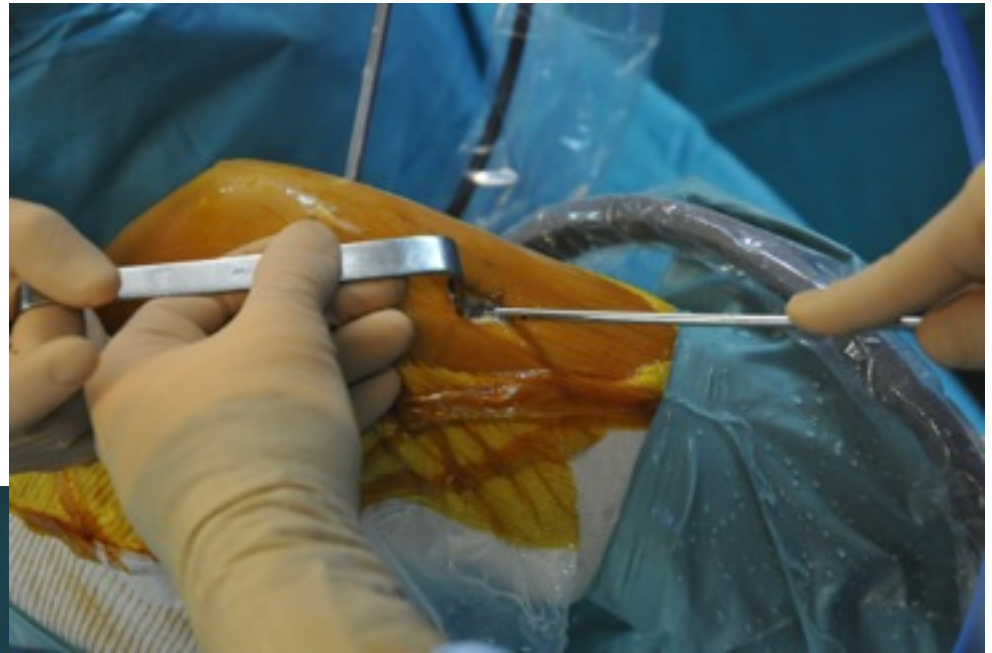PREPARATION OF TUNNEL TIBIAL



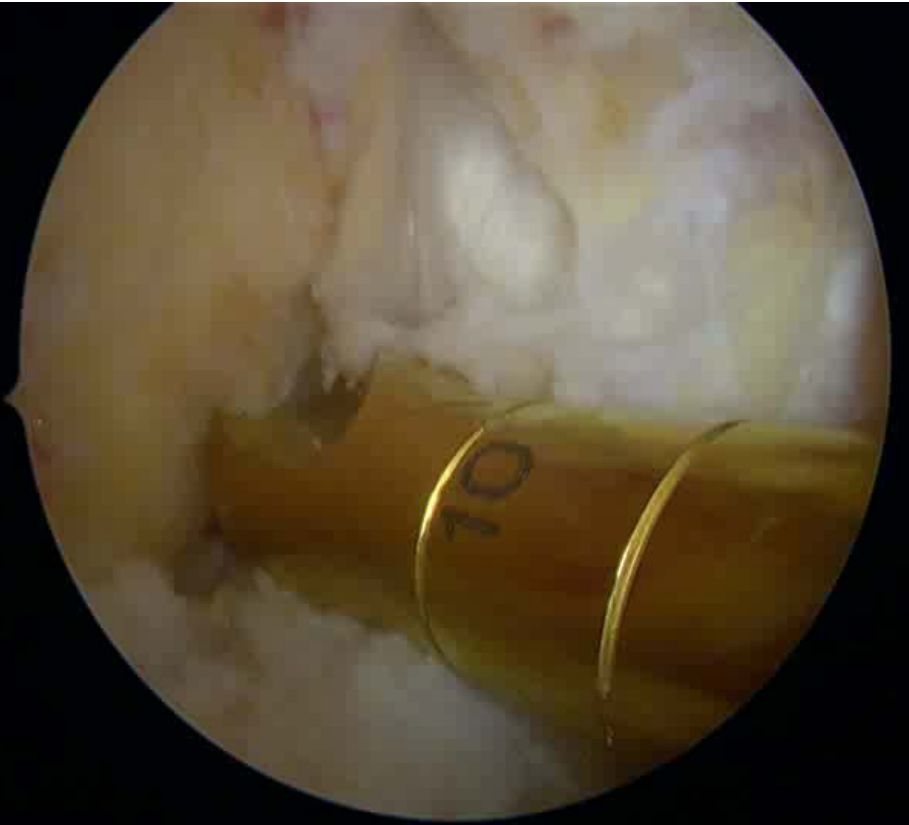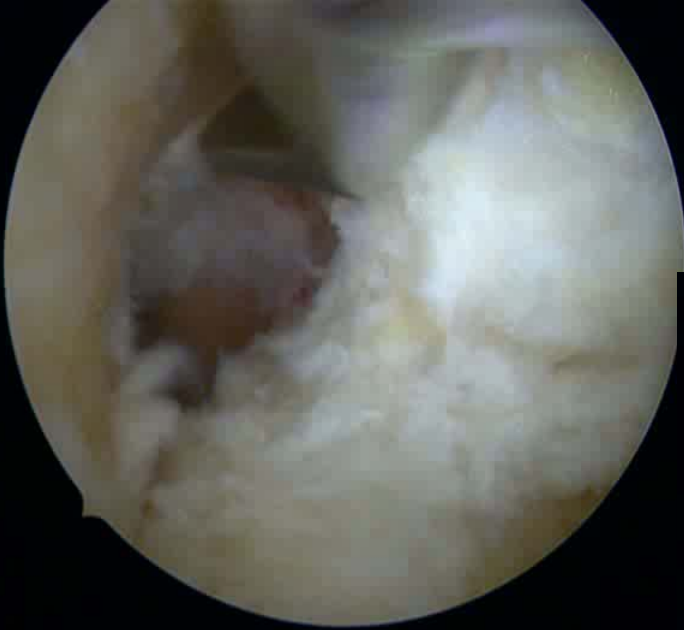PREPARATION OF TUNNEL TIBIAL



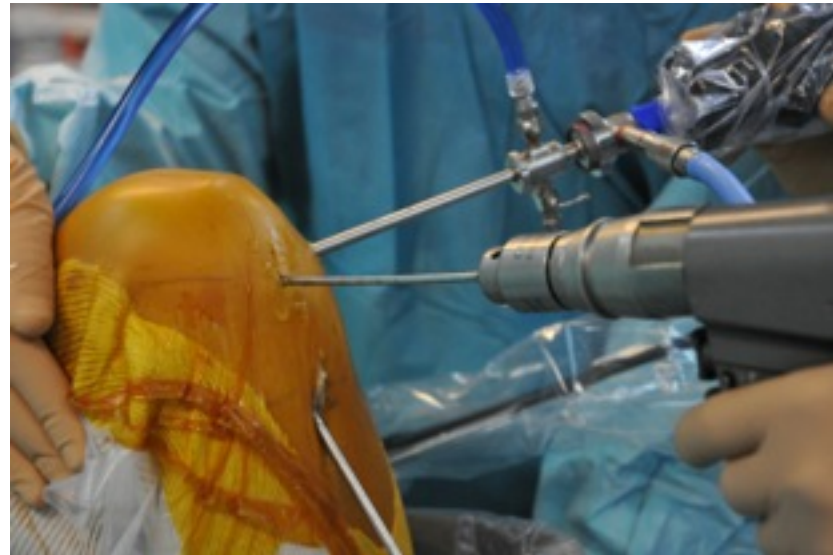
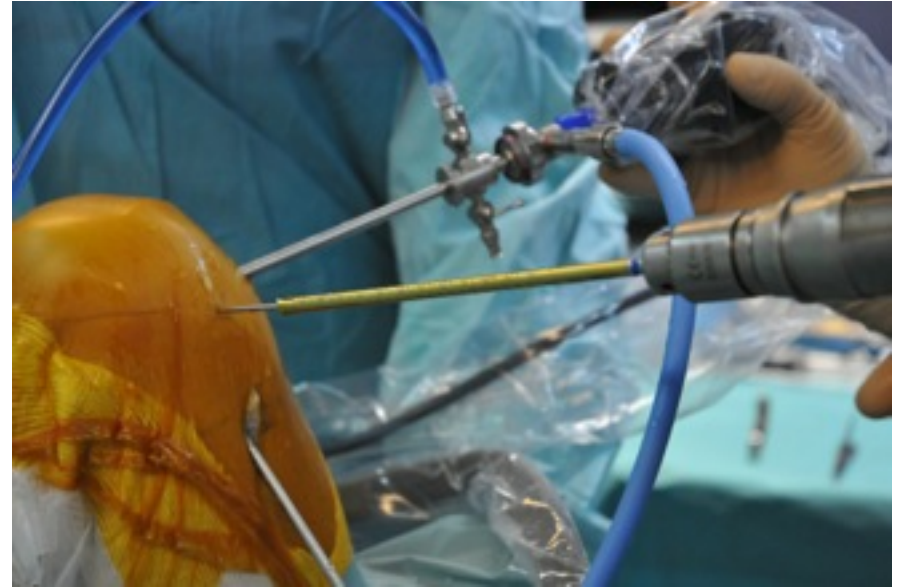
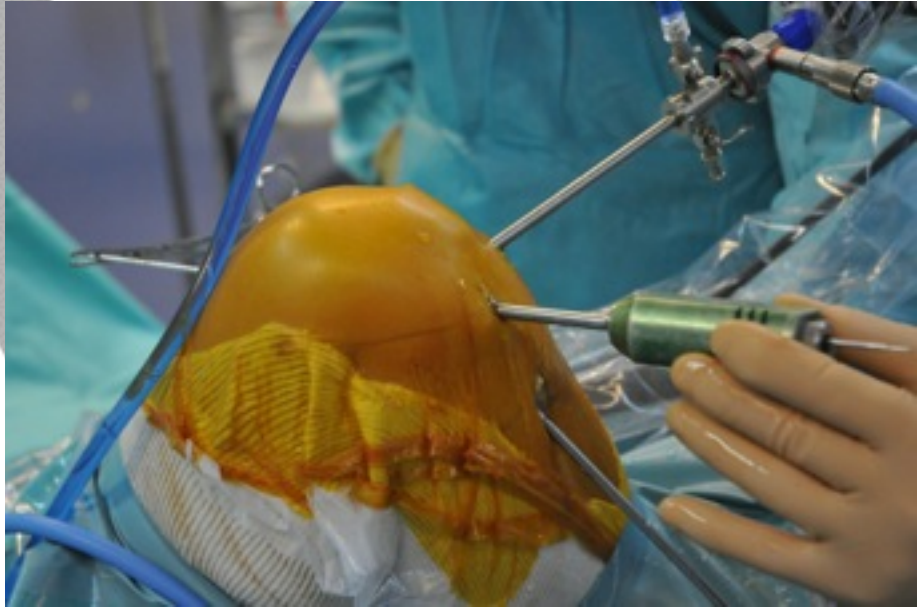PREPARATION OF TUNNEL TIBIAL



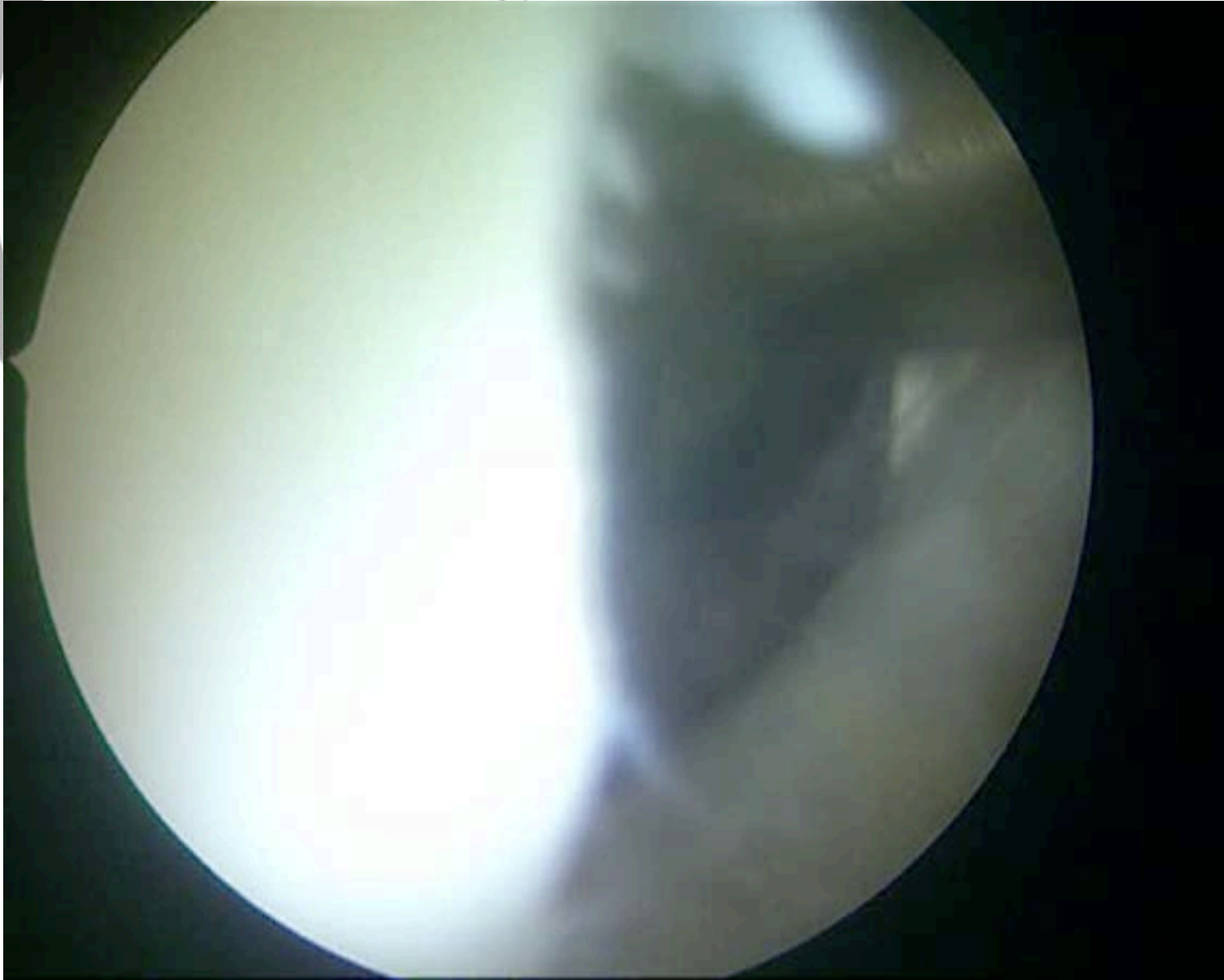
PREPARATION OF TUNNEL FEMORAL



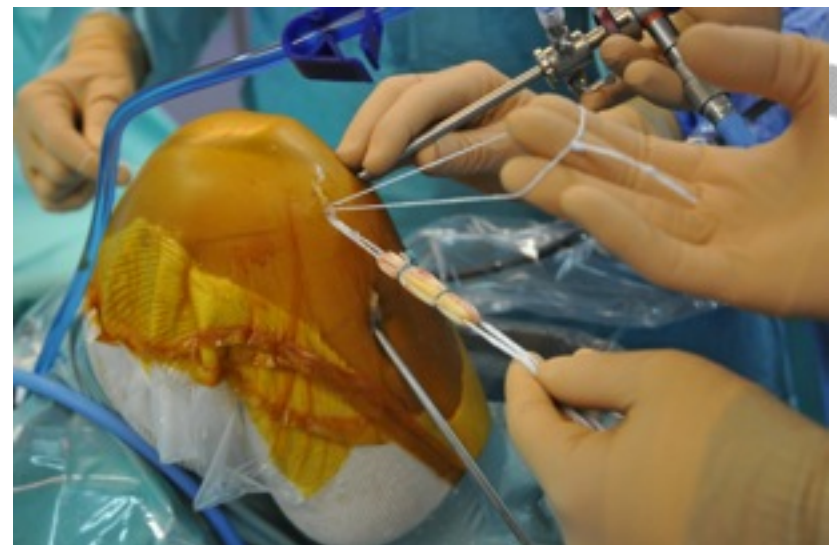
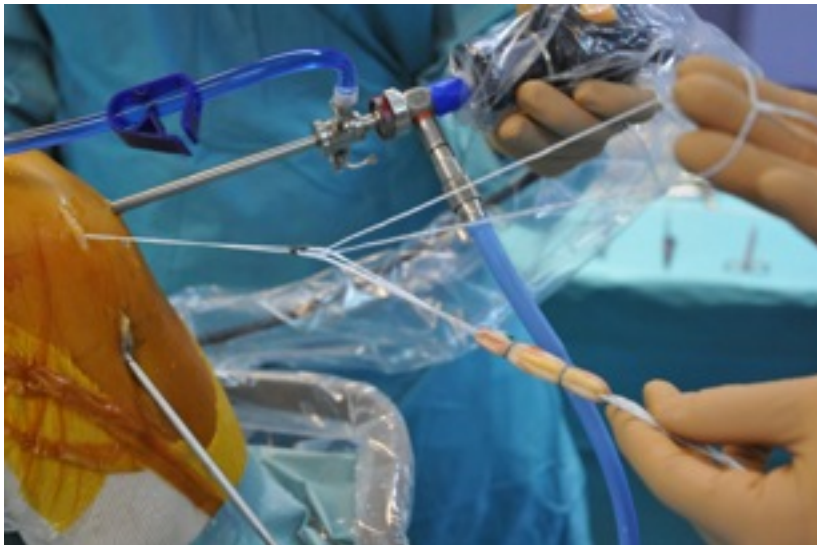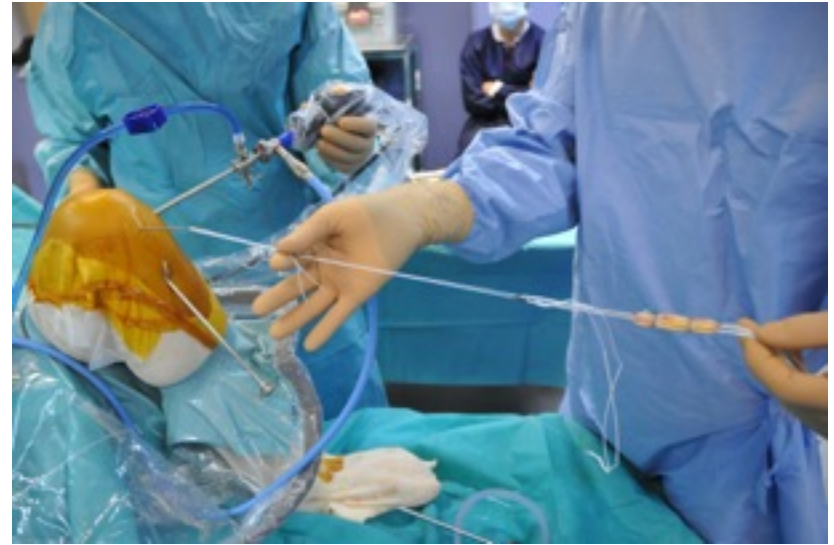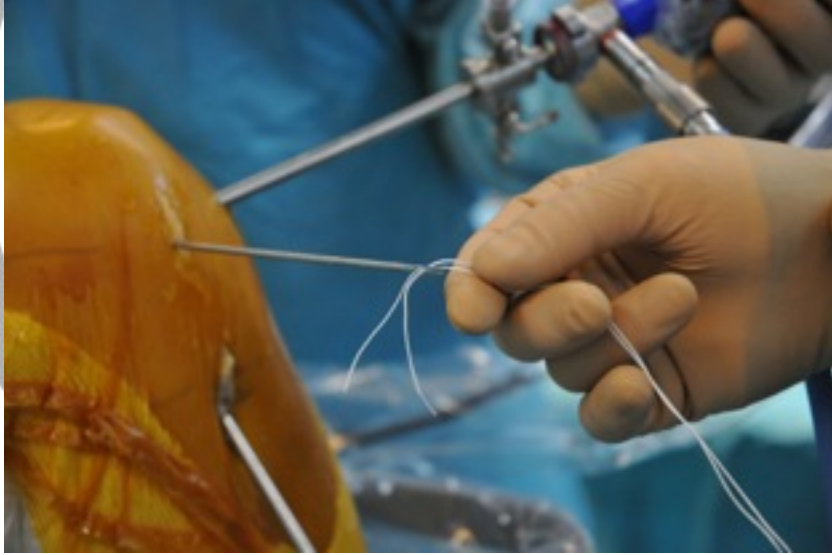PREPARATION OF TUNNEL FEMORAL

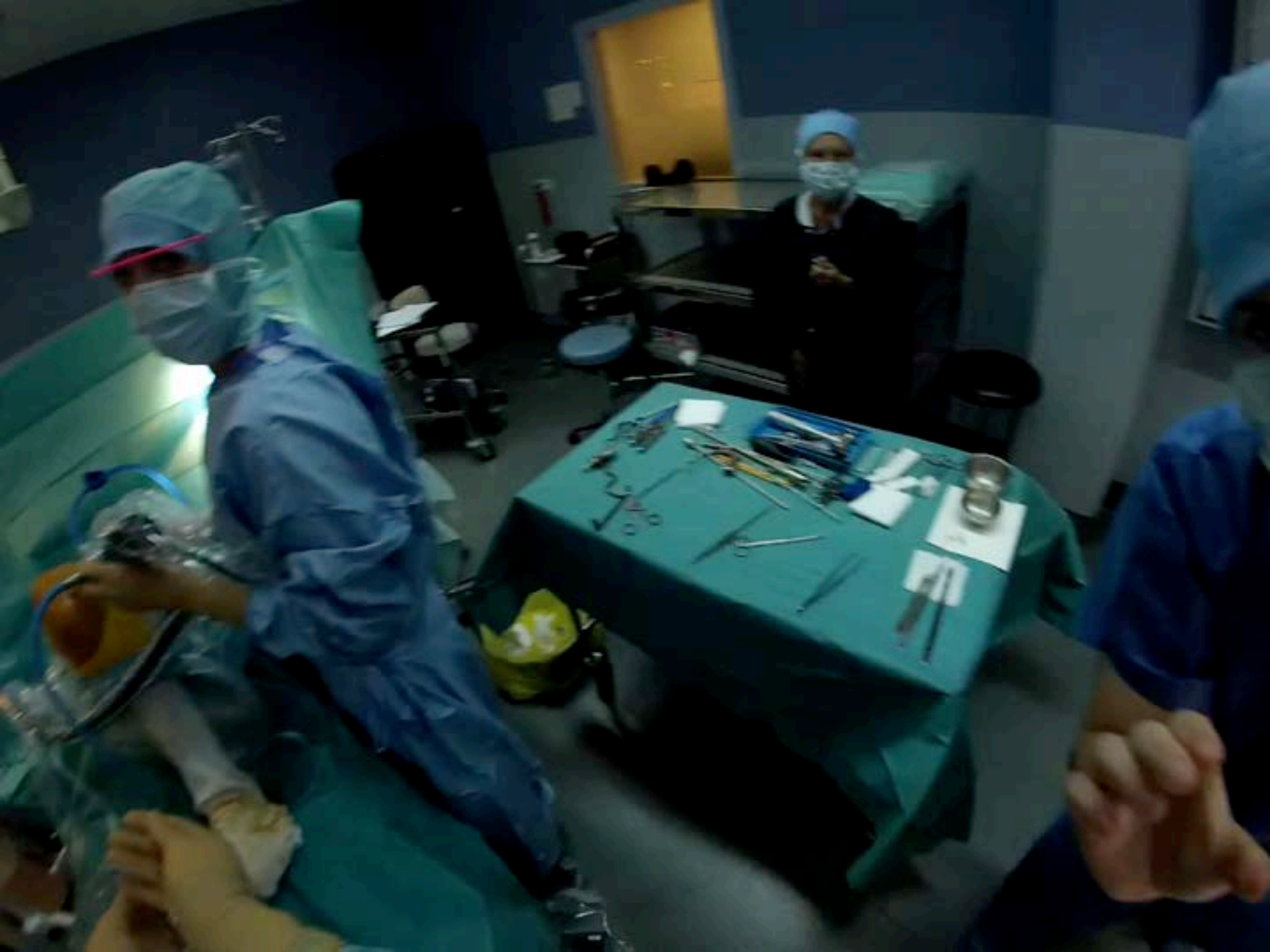

PREPARATION OF TUNNEL FEMORAL

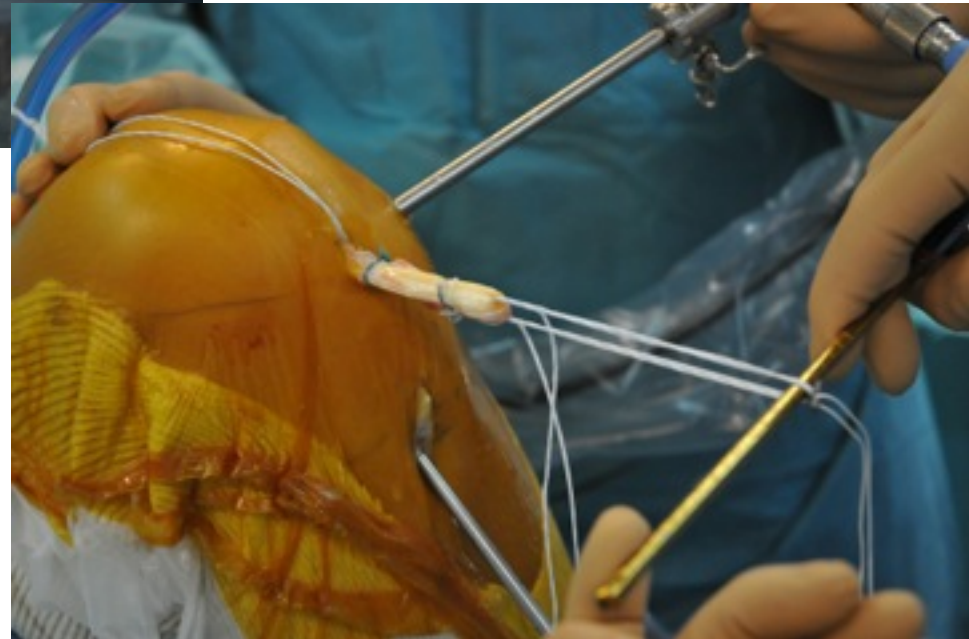
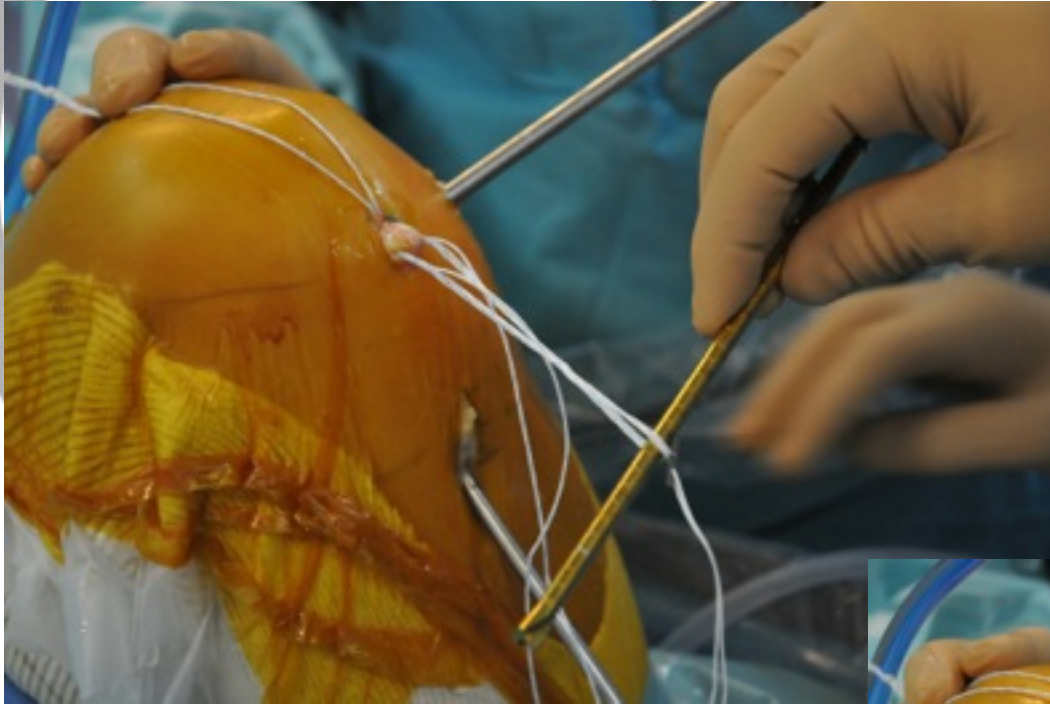
PASSAGE OF TOGGLELOC AND GRAFT

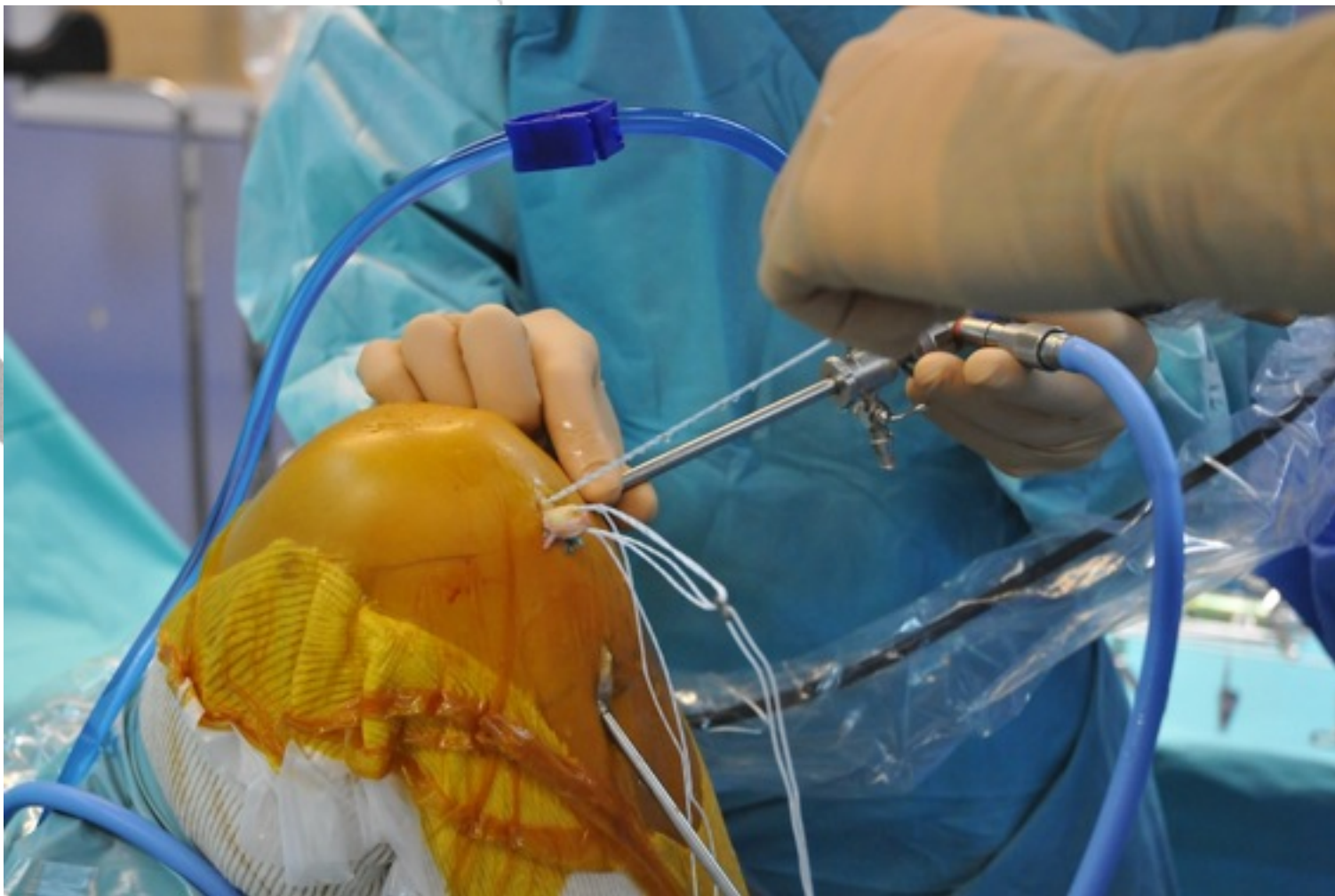

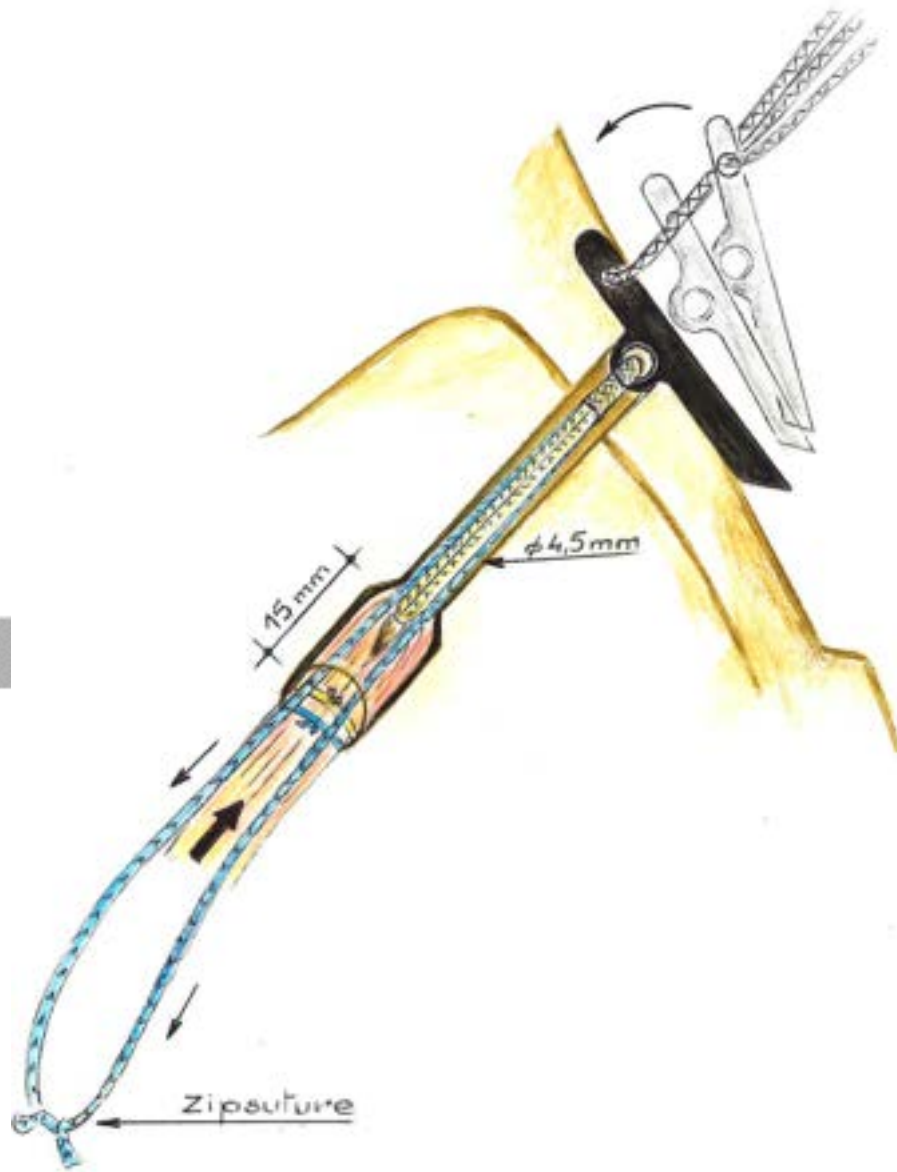


CORTICAL LOCKING OF TOGGLELOC

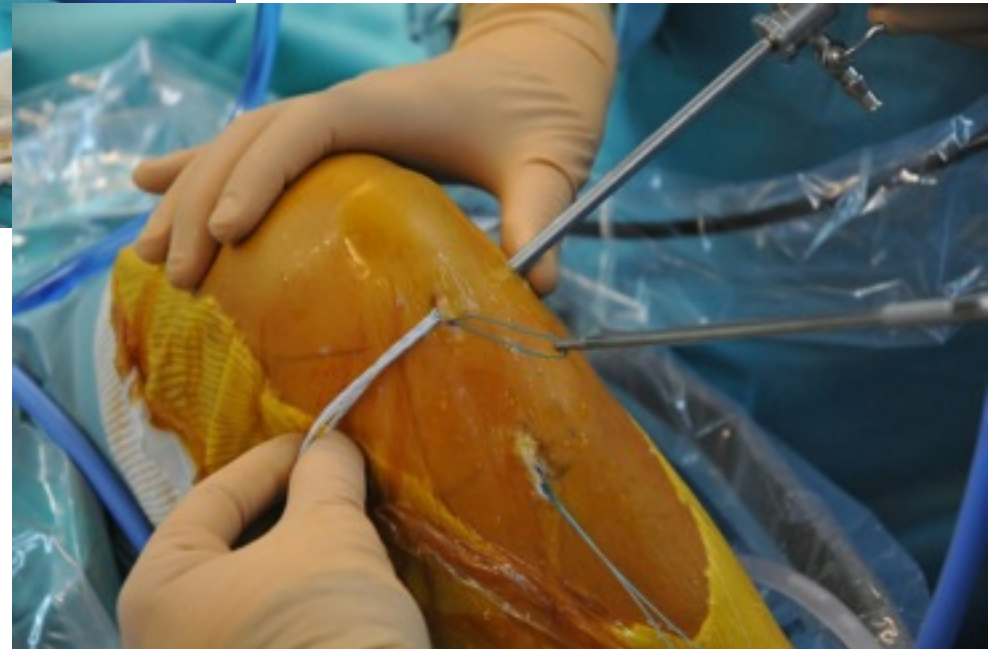
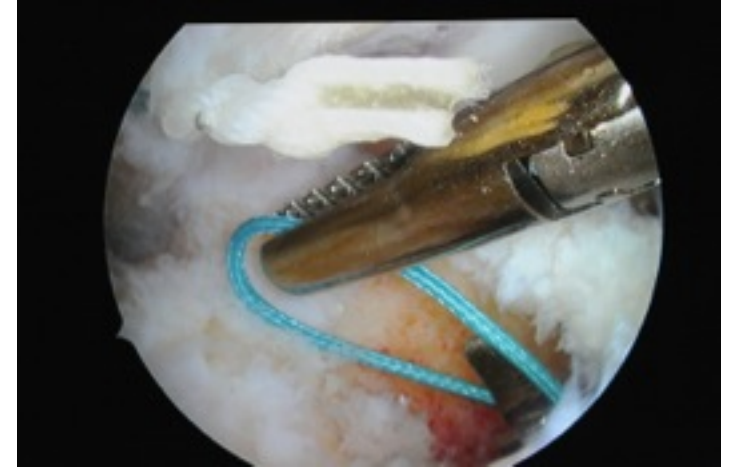
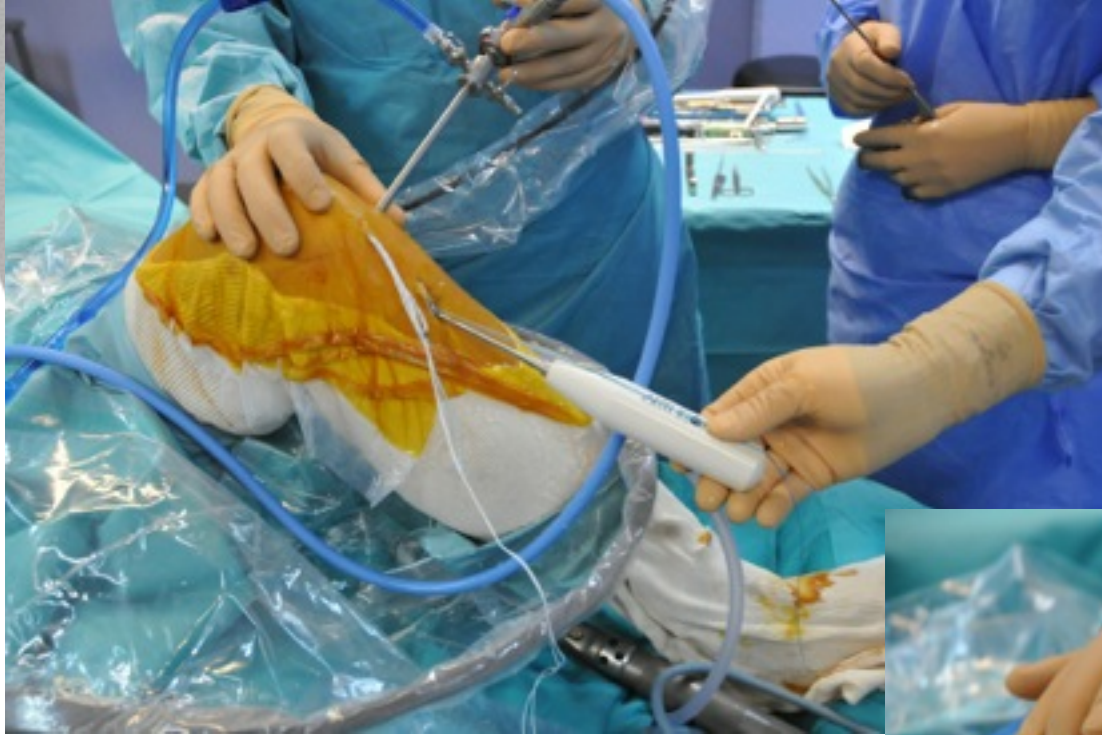
RISE OF THE TRANSPLANT

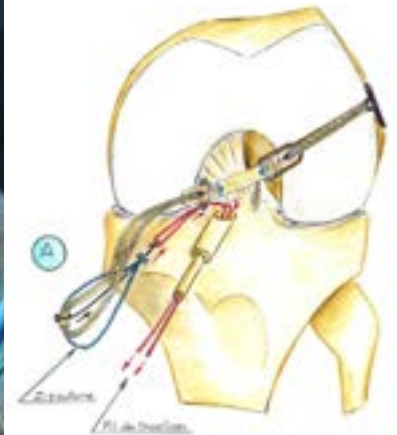
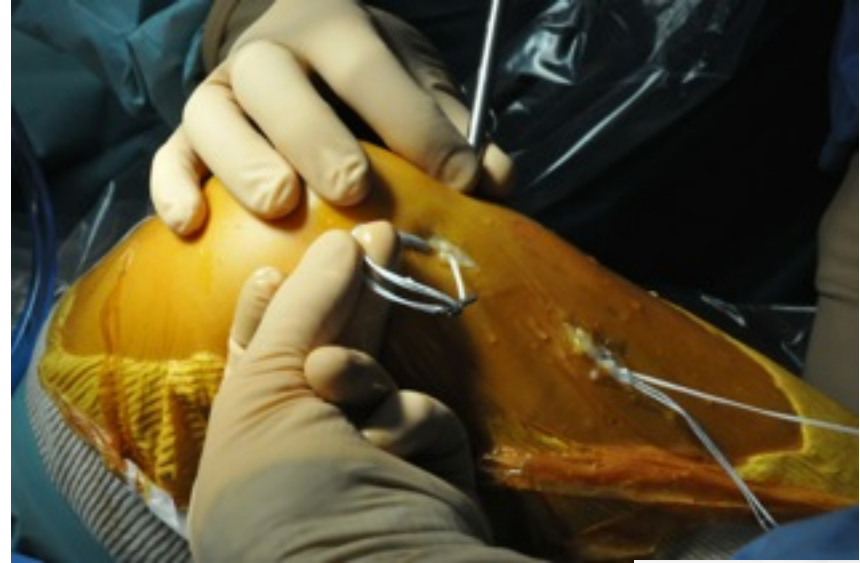
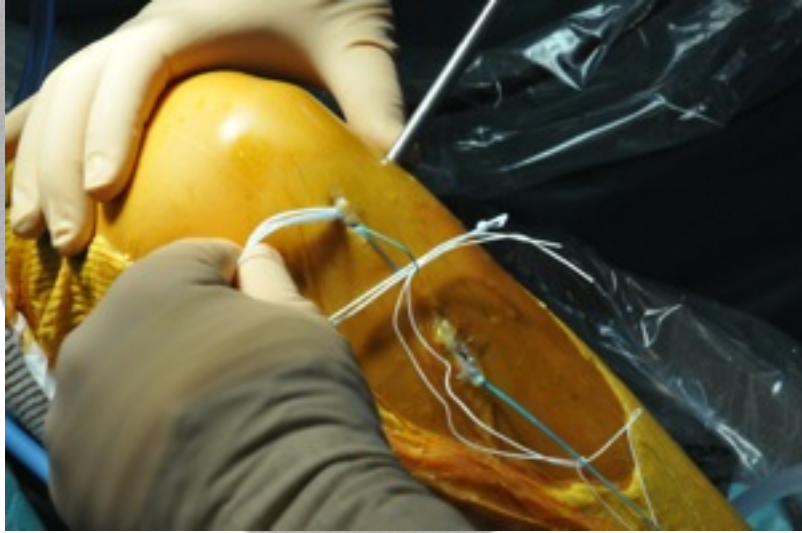


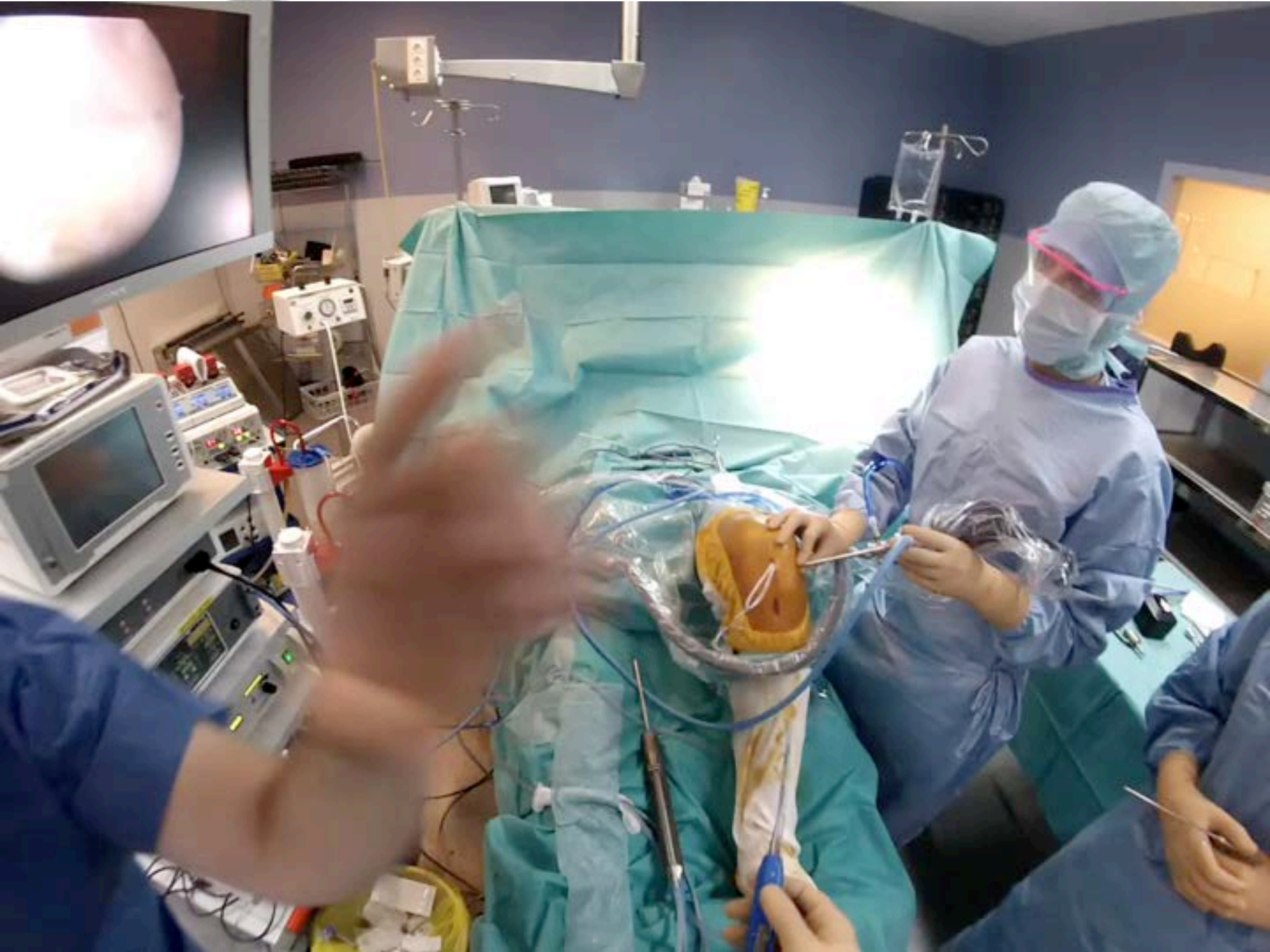PASSAGE INTRA-ARTICULAR OF TOWING THREAD

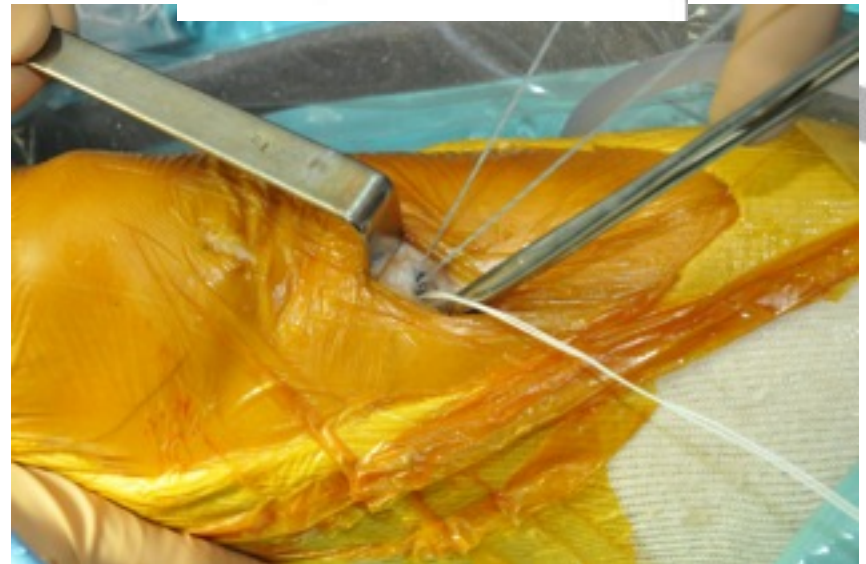
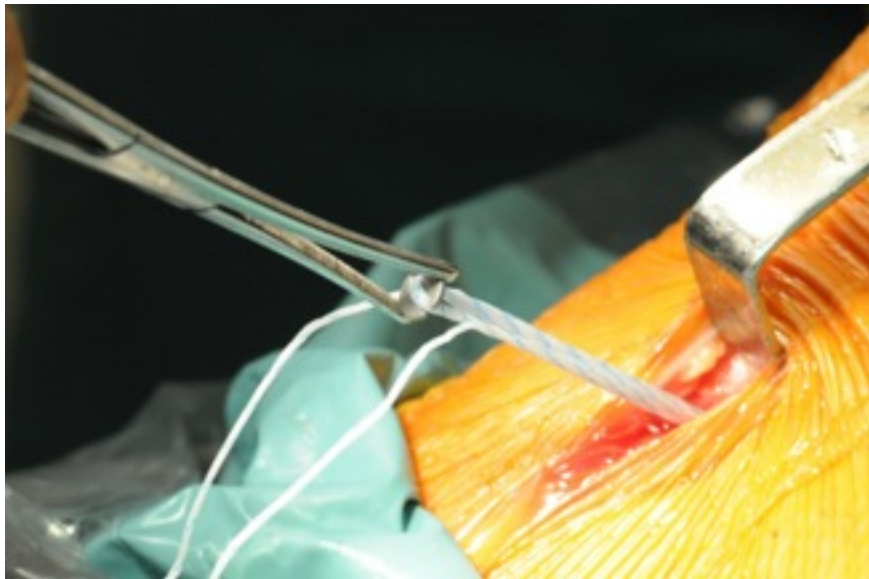
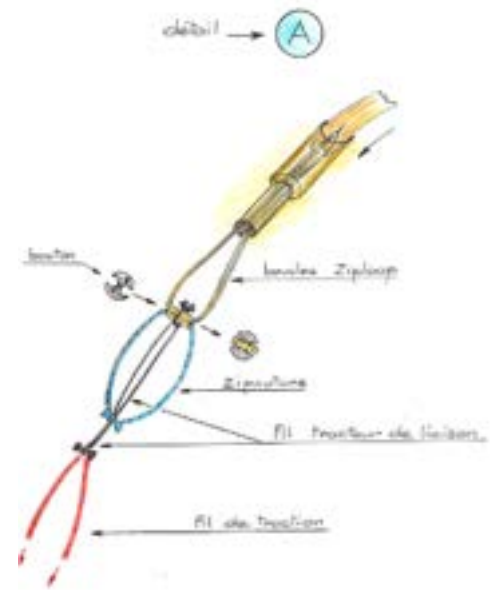
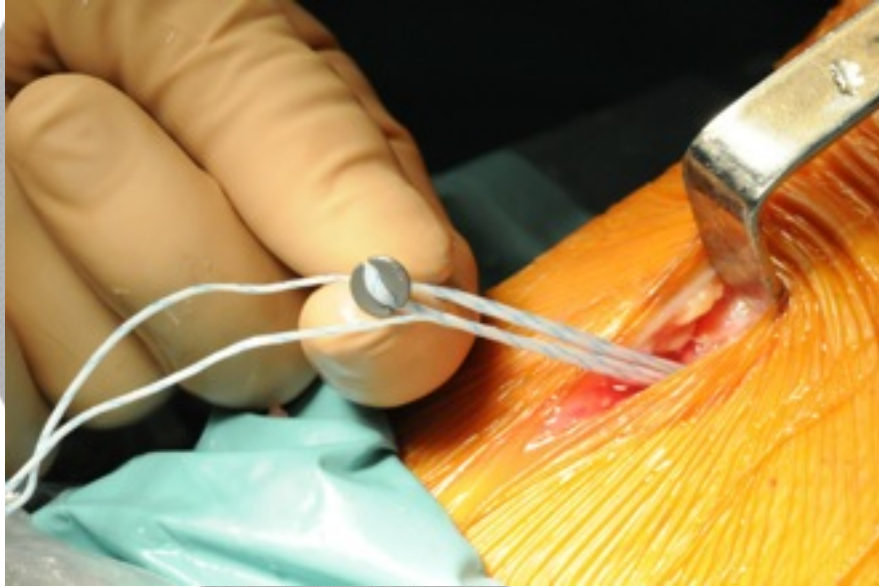


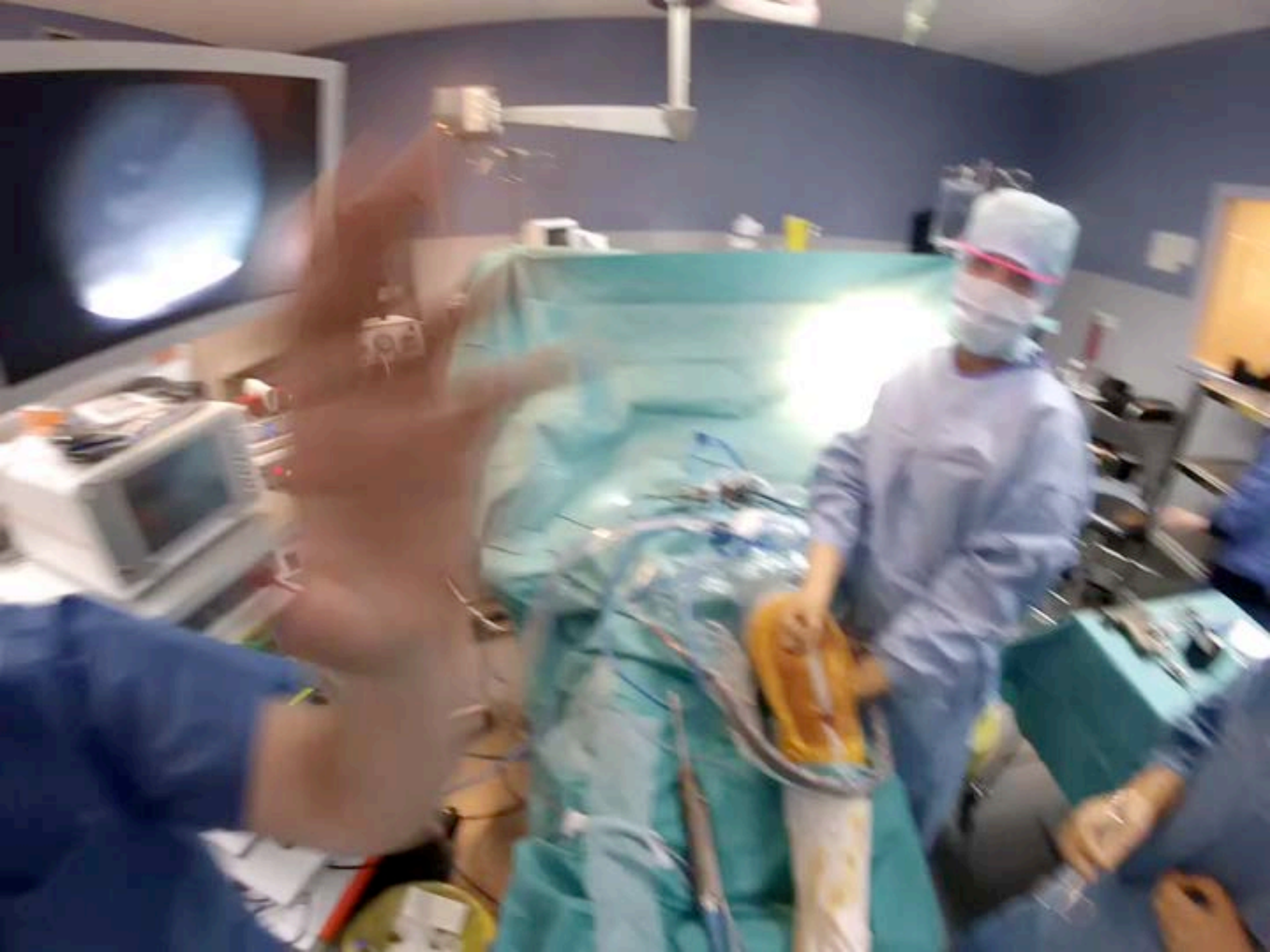PASSAGE INTRA-ARTICULAR OF ZIPLOOP INLINE LOOPS

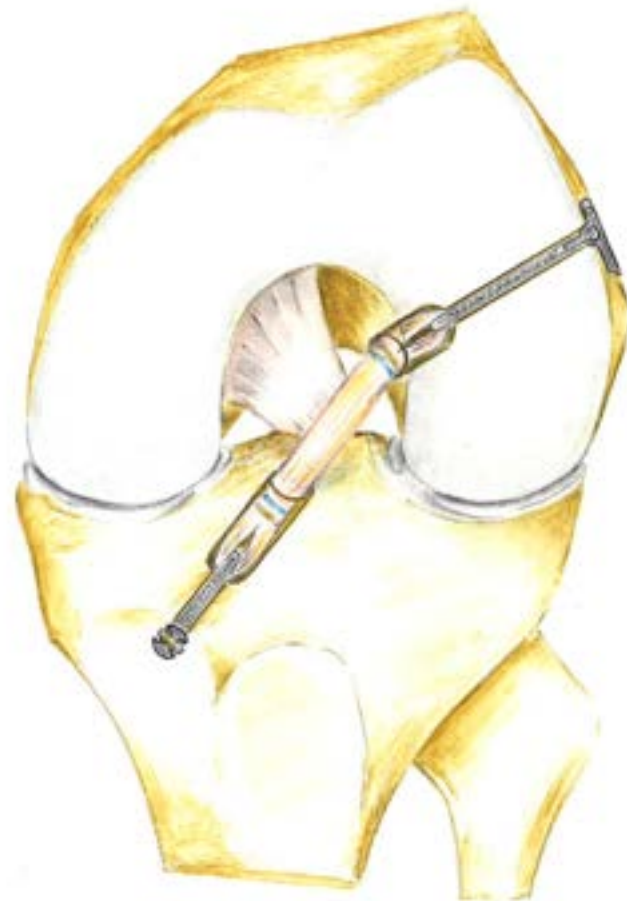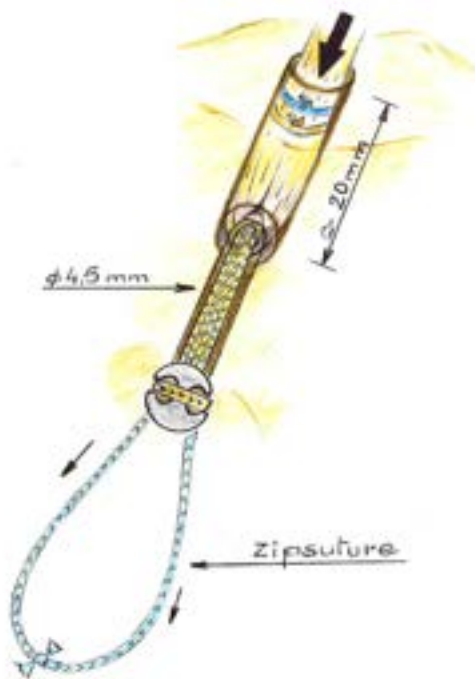




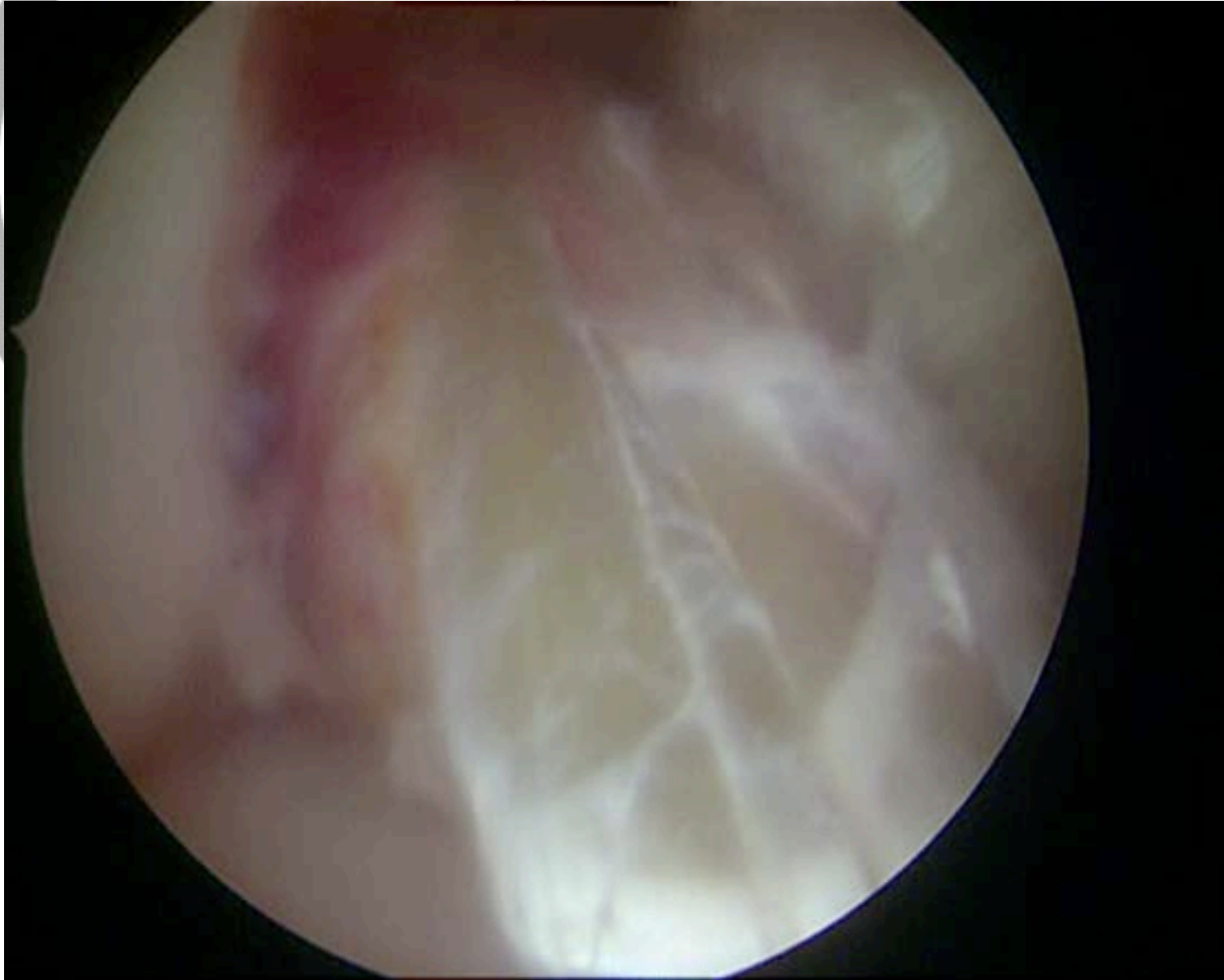
LOCKING ZIPLOOP INLINE



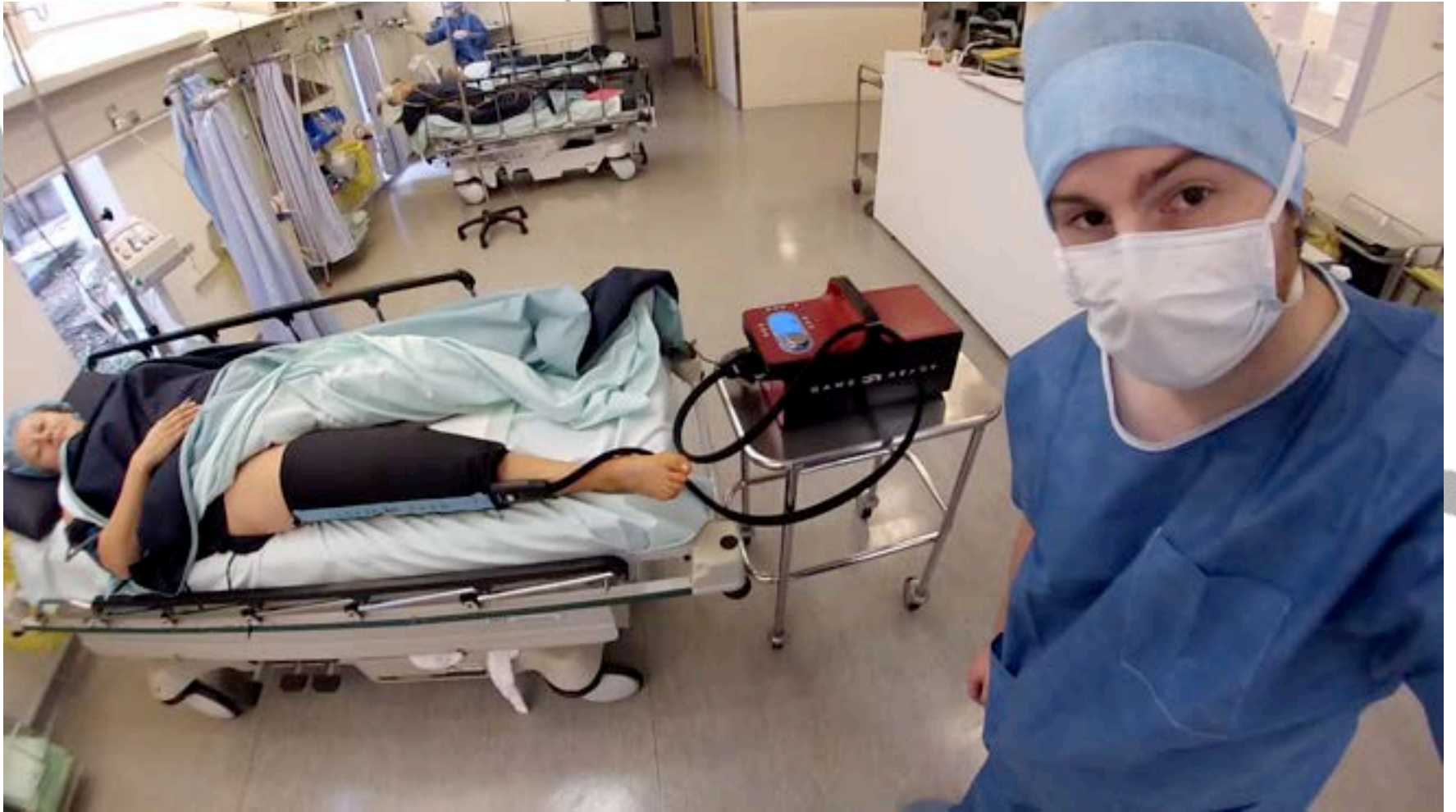



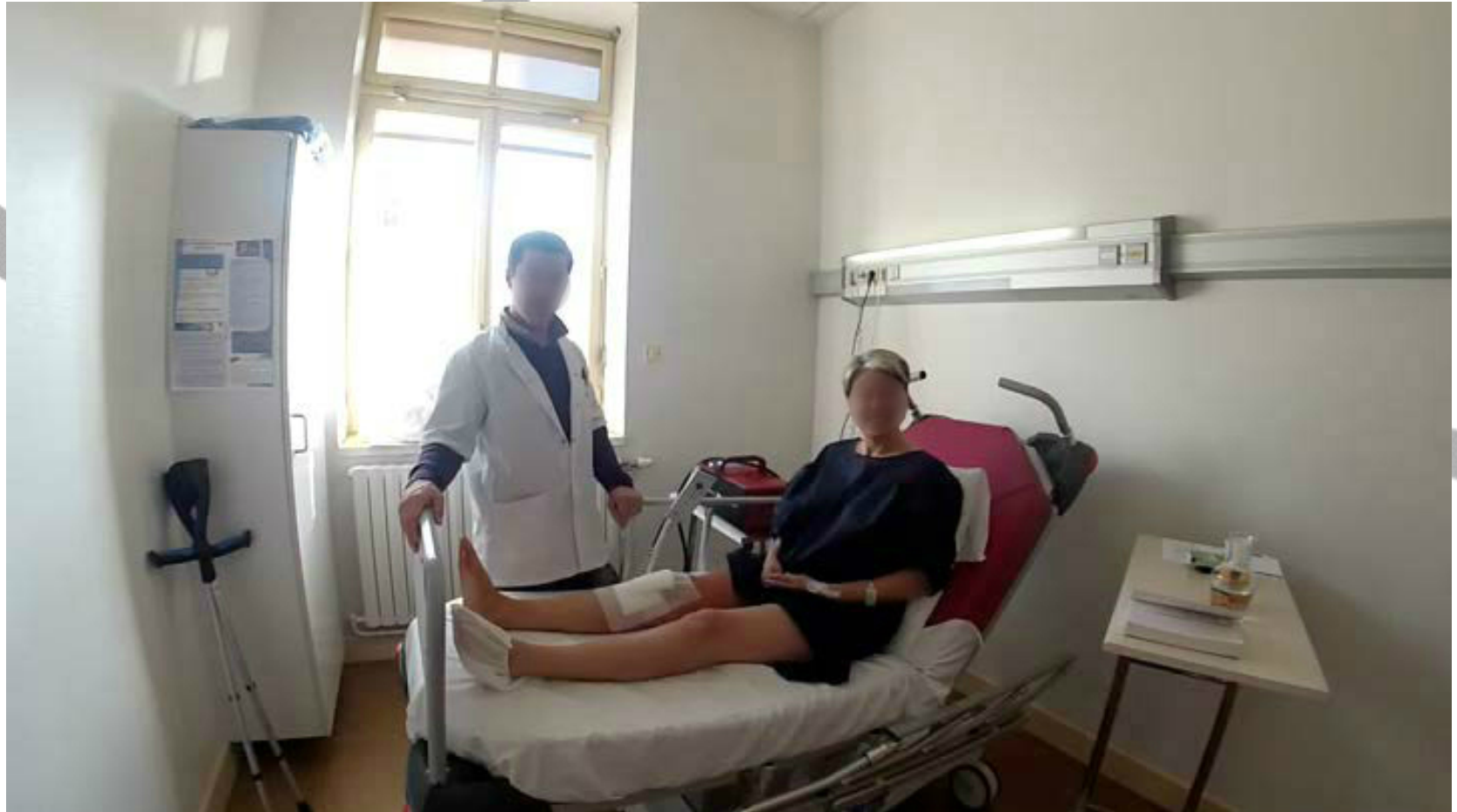TESTING FINAL STABILITY



GAME READY



PHYSIOTHERAPY



CHECK-IN OUT



